

# AVIAN CRYPTOSPORIDIOSIS: A SIGNIFICANT PARASITIC DISEASE OF PUBLIC HEALTH HAZARD

Wafaa A Abd El-Ghany

Poultry Diseases Department, Faculty of Veterinary Medicine, Cairo University, Giza, 12211 Giza Square, Egypt

\*Corresponding author, Email: wafaa.ghany@yahoo.com

**Abstract:** Cryptosporidiosis is one of the most important zoonotic parasitic diseases affecting a wide range of host species. The disease is widely distributed all over the world. *Cryptosporidium* species can affect different avian hosts, causing severe economic losses. The severity of avian cryptosporidiosis symptoms vary from asymptomatic disease to severe enteric and/or respiratory manifestations with high mortality. Diagnosis of *Cryptosporidium* infection is mainly based on microscopic detection of oocysts, serological methods, or molecular techniques to identify different *Cryptosporidium* species. Humans and animals are highly susceptible to infection by different *Cryptosporidium* species as a result of the ingestion of contaminated food and water by oocysts or direct contact with infected hosts. Different prevention and control strategies have been applied either in the surrounding environment or for the infected animals, birds, and humans. Therefore, this review article was designed to shed light on avian cryptosporidiosis species and its distribution, susceptibility and infection, clinical pictures, laboratory diagnosis, zoonotic importance in humans, and prevention and control strategies.

**Key words:** avian; control; *Cryptosporidium*; diagnosis; human

---

## Introduction

Cryptosporidiosis is a zoonotic enteric parasitic disease affecting humans, mammals, birds, and fish (1, 2). Globally, cryptosporidiosis is ranked fifth among the 24 most important foodborne parasites (3-5). Avian species could be infected with *Cryptosporidium* parasite with variable mortality and morbidity rates, causing great economic losses (6-10). The most important pathogenic species of *Cryptosporidium* that affect birds are *Cryptosporidium meleagridis* (*C. meleagridis*), *C. baileyi*, *C. galli*, and *C. avium* (11). In chickens and/or turkeys, infection is usually caused by *C. baileyi* and *C. meleagridis* (12), and rarely *C. parvum* (13) and *C. galli* (14). There are great differences in the prevalence and distribution rates of

*Cryptosporidium* species among various avian species. The clinical pictures of *Cryptosporidium* infections vary from intestinal to respiratory diseases according to the oocysts of each species, susceptibility and age of the birds, and presence of concurrent infections (15). Conventional microscopical staining techniques (16), serological methods, and recent molecular techniques are used for the diagnosis of cryptosporidiosis (17, 18). Several studies around the world demonstrated the zoonotic potential of *Cryptosporidium* species like *C. parvum*, *C. hominis*, and *C. meleagridis* in different hosts like dogs, cattle, mice, and cats. Humans, especially children and patients with immunodeficient diseases, could be infected through direct contact with infected animals (19) or birds (20). Application of hygienic measures, prevention of direct contact with infected animals or birds, and treatment of infected

animals, especially diarrheic animals or humans, are the most important strategies for the prevention and control of cryptosporidiosis.

Accordingly, this review article was designed to shed light on avian cryptosporidiosis distribution, susceptibility and infection, clinical pictures, laboratory diagnosis, zoonotic importance in humans, and prevention and control strategies.

## History and distribution

Table 1 show the incidence and distribution of *Cryptosporidium* species in different avian hosts all over the world. The first detection of avian *Cryptosporidium* oocysts was in the cecum of apparently healthy chickens (21) as these oocysts were similar to *C. parvum* and *C. hominis* in humans. Later, for the first time, a unique *Cryptosporidium* species was described as *C. meleagridis* by Slavin (22), and this species was molecularly differentiated from *C. parvum* as a different avian species with zoonotic nature (23). In an Algerian study by Baroudi et al. (24), the prevalence rates of *C. meleagridis* were 57.9%, 43.9%, and 5.5% in turkey poults, adult turkeys, and broiler chickens, respectively. However, the infection rate of *C. meleagridis* in chickens of the previous study was 28.9%.

Furthermore, *C. meleagridis* was previously found in 5% (25), 3% (26), and 3.2% (27) of broiler chickens and 10% of layer chickens in China (28) and in 9% of broilers in Algeria (29).

Another species of *Cryptosporidium* called *C. baileyi* was detected in the intestinal tracts, bursae of Fabricius, and cloacae of birds (30), in the upper and lower respiratory tracts of broilers (31, 32, 26) and geese (33), and in the urinary tract as kidneys (34, 35). Recently, *C. baileyi* was molecularly detected in broiler and layer chickens, ducks, and pigeons as a zoonotic species (36, 27, 37). It has been documented that *C. baileyi* is the most prevalent avian *Cryptosporidium* species worldwide and has a wide host range (38-41, 28, 11, 42).

Although *C. parvum* has zoonotic importance in humans, it is sporadically found in poultry species (11). In 2017, in Germany, the prevalence rates of *Cryptosporidium* species were 5.7% in broilers and 8.3% in layers, and *C. parvum* was the most predominant isolate of chickens and turkeys (20, 40). In Brazil, *C. parvum* was detected in chicks (15), while in the United States it was detected in turkeys (43).

Other species of *Cryptosporidium* have also been identified earlier. Levine (44) found *C. tyzzeri* in chickens, while Proctor and Kemp (45) found *C. anserinum* in geese. In 1990, *C. blagburni* was identified in finches (46, 39), but this species was further described as *C. galli* with a zoonotic nature. The latter was previously identified in chickens' proventriculi (47, 48, 14).

Different avian species of *Cryptosporidium* have been reported among Egyptian poultry flocks. The first morphological detection of *C. meleagridis*, *C. baileyi*, and *C. galli* was in quails in 2011. The study showed that the prevalence rates of *Cryptosporidium* oocysts were 30.8% in bobwhite quails and 33.3% in brown quails with a total percentage of 31.9% (49). From a wide range of avian species in different seasons, *Cryptosporidium* in all the examined bird species was prevalent in winter (15.4% for fowl, 3.6% for pigeons, 44.2% for ducks, 15.7% for turkeys, and 30% for geese), while the lowest prevalence rate of *Cryptosporidium* was in spring (8.3% for fowl and 2.6% for pigeons). *Cryptosporidium* showed less incidence in ducks in autumn (2.4%) and summer (3.2%) and in turkeys (4.4%) (50). In the study of Kalifa et al. (51), the incidence of *Cryptosporidium* species in ducks was 39.9%, with the highest rate in winter (74.6%) and the lowest rate in autumn (7.1%). Approximately 55% of 100 ducks had antibodies against cryptosporidiosis. The molecular analysis revealed positive amplification at 435 bp, and sequencing confirmed the presence of *C. meleagridis*.

Genetically, five genotypes of *Cryptosporidium* (I, II, III, IV, and V) were identified in birds (9, 52). In Canada, genotypes I to V were identified in wild geese and the black duck (53, 54). Genotype I was detected in canaries and Indian peafowl (41, 55). Genotype II was found in ostriches (56, 57) and other several species of Psittaciformes and Passeriformes (41, 58-62). Genotype IV was identified in Japanese white-eye woodcocks, in addition to the Eurasian woodcock genotype that was detected in Eurasian woodcocks (41). Genotype V was found in cockatiels (52), Psittaciformes (59, 62), and reptiles (63). Phylogenetically, *C. meleagridis*, *C. baileyi*, goose genotypes I and II, and the duck genotype belong to the *Cryptosporidium* intestinal clade, while *C. galli*, *C. andersoni*, *C. muris*, *C. serpentis*, and genotypes III and IV belong to the gastric clade (64, 41).

**Table 1:** Incidence and distribution of *Cryptosporidium* species in different avian hosts all over the world

Country	Incidence and distribution	Reference
	<i>C. baileyi</i> , <i>C. galli</i> , and <i>C. meleagridis</i> have been characterized in ostriches using morphological, biological, and molecular techniques.	[9]
	<i>C. baileyi</i> was found in ducks and quail, while <i>C. meleagridis</i> was detected in chicken.	[36]
	Positive amplification for <i>Cryptosporidium</i> species was observed in 12.6% (24/190) of the samples, including <i>C. baileyi</i> (9.8%; 18/190), <i>C. meleagridis</i> (0.5%, 1/190), <i>C. parvum</i> (2.1%; 4/190), and <i>Cryptosporidium</i> species (0.5%; 1/190). Sub-genotyping of <i>C. meleagridis</i> revealed the presence of the subtype IIIgA23G3R1.	[42]
	Sequencing of <i>Cryptosporidium</i> species revealed presence of <i>C. baileyi</i> in a black vulture, a domestic chickens, and a saffron finch; <i>C. galli</i> in canaries, a cockatiel, and lesser seed-finches; <i>C. meleagridis</i> in a domestic chicken; <i>C. parvum</i> in a cockatiel; <i>Cryptosporidium</i> avian genotype I in a canary and an Indian peafowl; <i>Cryptosporidium</i> avian genotype II in ostriches, and <i>Cryptosporidium</i> avian genotype III in a cockatiel and a peach-faced lovebird.	[55]
	Molecular analysis of nucleotide sequences grouped the ostrich isolate of <i>Cryptosporidium</i> species as <i>C. baileyi</i> which was genetically distinct from all other species.	[56]
	Among the 242 fecal samples from wild birds, 16 (6.6%) were positive for the presence of <i>Cryptosporidium</i> . Molecular characterization of 16 samples showed <i>C. meleagridis</i> . <i>C. galli</i> was identified in rufous-bellied thrush, green-winged saltators, slate-coloured seedeater, goldfinch, and saffron finches. Isolates in Goldfinch isolate, buffy-fronted seedeater, red-cowled cardinal, and saffron finch isolates were identified as <i>C. baileyi</i> . Avian genotype II was found in an isolate from a white-eyed parakeet.	[60]
Brazil	Out of 103 fecal samples of exotic birds, 7 (6.8%) were positive for <i>Cryptosporidium</i> . Sequencing analyses showed <i>C. parvum</i> in Bengalese finch and avian genotype III in Java sparrow and cockatiel. The sequences of the <i>Cryptosporidium</i> species isolated from canaries presented a higher genetic similarity with <i>C. parvum</i> .	[61]
	A total of 1027 fecal samples were collected from Psittaciformes and Passeriformes. Molecular analysis showed positive results in 580 (56.47%) and 21 (2.04%) samples, respectively, for <i>C. galli</i> and <i>Cryptosporidium</i> avian genotype II, and in 28 (2.73%) and 3 (0.29%) samples, respectively, for <i>C. galli</i> and <i>Cryptosporidium</i> avian genotype III. <i>C. baileyi</i> and <i>Cryptosporidium</i> avian genotype V were also identified.	[62]
	Microscopic examination of fecal smears of carrier pigeons revealed presence of 4% (4/100) positive <i>Cryptosporidium</i> . While, 7% (7/100) were molecularly positive. <i>C. parvum</i> was genetically identified.	[75]
	<i>C. baileyi</i> was identified in broiler chickens. This species was able to infect Japanese quails.	[79]
	<i>Cryptosporidium</i> was observed in 44.4% of the examined 77 ostriches. However, 100% of the ostriches shed oocysts in their feces.	[86]
	<i>C. galli</i> infection was microscopically, histologically, and molecularly characterized in canaries, a cockatiel, and in lesser seed-finches with clinical complaints of apathy and sporadic mortality.	[134]
	<i>Cryptosporidium</i> species were detected in 24.5% samples of adult and 13% of young species of birds including great-billed seed-finch, lesser seed-finch, ultramarine grosbeak, and rusty-collared seedeater. The sequencing analyses showed identification of <i>C. galli</i> . The protozoon infection was associated with concomitant infection with <i>Escherichia coli</i> and <i>Isospora</i> species.	[135]

**Table 1:** continuation

	<i>Cryptosporidium</i> species were microscopically demonstrated in young quails experienced high mortality, diarrhea, and clear fluid content in the intestine.	[6]
	<i>Cryptosporidium</i> species and reovirus were identified in bobwhite quails with white-watery diarrhea, dehydration, and death, 30%-45% mortality rate, and mucoid enteritis.	[7]
	The overall 23 of 56 (41%) broiler chickens had <i>C. baileyi</i> tracheitis. The infection rates among <i>C. baileyi</i> -infected flocks ranged from 10%-60%.	[32]
	<i>Cryptosporidium</i> species were microscopically detected in the urinary tract of adult laying hens.	[35]
	<i>C. parvum</i> was found in turkeys, especially in 4-9-week-old birds.	[43]
	Genotypes I to V of <i>Cryptosporidium</i> were identified in wild geese.	[53]
	<i>Cryptosporidium</i> goose genotype I, <i>Cryptosporidium</i> goose genotype II, <i>Cryptosporidium</i> duck genotype, <i>C. parvum</i> , and <i>C. hominis</i> were identified.	[54]
	Oocysts of <i>Cryptosporidium</i> species were observed in the feces, and the developmental stages of the parasite were observed in tissue sections of turkeys and Muscovy ducks but not bobwhite quail.	[66]
	Oral inoculation of ducks with <i>C. baileyi</i> induced no clinical signs, while intratracheal inoculation produced mild respiratory disease, no deaths, and airsacculitis.	[69]
	Proventriculus and intestinal samples from 70 North American red-winged blackbirds were examined. Twelve birds (17.1%) were genetically positive for the <i>Cryptosporidium</i> . Sequence analysis of the gastric species revealed presence of <i>C. galli</i> and <i>Cryptosporidium</i> avian genotype VI.	[90]
	Microscopic examination of the intestinal contents of turkey poults suffering from diarrhea and mucoid enteritis and typhlitis showed presence of <i>Cryptosporidium</i> species in the enterocytes, villi atrophy, and infiltration with inflammatory cells.	[95]
The United states	<i>Cryptosporidium</i> oocysts were detected in the droppings of 16/20 (80%) 17-day-old and of 38/100 (38%) 24-day-old turkeys without signs. The protozoon was frequently found in the ceca, colon, and cloaca of inoculated turkeys and chickens.	[98]
	Outbreaks of sinusitis due to <i>Cryptosporidium</i> were documented in 7-and 3-week-old turkeys.	[100]
	Concurrent infection with <i>Mycoplasma sturni</i> and <i>Cryptosporidium</i> species was detected in cliff swallows manifested clinical, gross, and microscopic lesions.	[106]
	Mixed infection with <i>C. baileyi</i> and infectious bursal disease virus resulted in more severe bursal lesions, more infected birds, and greater numbers of the parasite in infected tissues.	[114]
	Double infection with <i>C. baileyi</i> and either reovirus promoted shedding of both. Reovirus infection did not modify lesions caused by <i>C. baileyi</i> infection.	[115]
	<i>Cryptosporidium</i> infection promoted systemic spread of reovirus, and reovirus intensified <i>Cryptosporidium</i> infection, but no significant synergistic effect on mortality or weight gain was observed.	[126]
	<i>Cryptosporidium</i> species were detected during histologic examination of small intestine from a budgerigar with chronic weight loss and from a cockatiel that died acutely.	[128]
	<i>C. baileyi</i> was microscopically detected in the small intestine of cockatiels.	[129]
	<i>Cryptosporidium</i> avian genotype III was demonstrated in lovebird ( <i>Agapornis</i> species) manifested gastrointestinal signs and lesions.	[136]
	Mixed infection with adenovirus and <i>Cryptosporidium</i> species was demonstrated during examination of tracheal mucosa of 7-week-old broiler chickens that had excessive exudate in the tracheas and congestion of the nasal turbinates.	[139]

**Table 1:** continuation

	The phylogenetic analysis supported the existence of <i>C. baileyi</i> and <i>C. meleagridis</i> in finches, a black duck, and brown quail.	[39]
	Of 430 avian-derived fecal specimens, 27 <i>Cryptosporidium</i> -positive isolates were detected and characterized. Genotypes I to IV were molecularly identified. <i>C. galli</i> , <i>C. muris</i> , and <i>C. andersoni</i> were also identified in a tawny frogmouth and a quail-crested wood partridge.	[41]
Australia	<i>Cryptosporidium</i> infection was found in 4-week-old quails with respiratory lesions and shrunken bursa of Fabricius. Deciliation, hyperplasia, and inflammatory cell infiltration in the respiratory cells and in the oesophageal and salivary glands were detected. Besides, follicular bursal atrophy and presence of <i>Cryptosporidium</i> species were observed.	[76]
	<i>Cryptosporidium</i> associated conjunctivitis was detected in 8-week-old ducks with conjunctivitis.	[101]
	Respiratory cryptosporidiosis was diagnosed in a 2-week-old peacock chicks. Microscopic examination of conjunctiva, nasal-sinus, and trachea showed the different developmental stages of <i>Cryptosporidium</i> .	[104]
	<i>C. meleagridis</i> was detected in an Indian ring-necked parrot using morphological and molecular methods.	[130]
	Histological examination and antigenic diagnosis by enzyme-linked immunosorbent analysis revealed the presence of <i>Cryptosporidium</i> species in respiratory and intestinal tracts of red-legged partridges. Morbidity (diarrhoea and cough) was 60%-70% and mortality was 50%. <i>C. meleagridis</i> was molecularly identified in faecal samples.	[10]
Spain	Intestinal cryptosporidiosis was identified in young pigeons manifested diarrhea and body weight loss. Hyperplasia of the intestinal crypts with inflammatory infiltration were seen.	[71]
	An ocular and respiratory disease were associated with <i>C. baileyi</i> infection in wild scops owl. Molecular analysis confirmed the presence of <i>C. baileyi</i> in the conjunctival cells and the nasal respiratory epithelium.	[89]
	Developmental stages of <i>Cryptosporidium</i> were observed in tracheal epithelium of turkey poults. Lesions associated with the parasite included excess mucus, epithelial hyperplasia, metaplasia, and necrosis, and infiltration with macrophage and heterophil in thickened lamina propria.	[65]
Canada	<i>Cryptosporidium</i> species were found in the feces of 14 out of 165 (8.5%) ostriches. The oocysts failed to infect chickens, turkeys, or quail. <i>Cryptosporidium</i> species from ostriches was different from <i>C. meleagridis</i> , <i>C. baileyi</i> , and <i>Cryptosporidium</i> species of bobwhite quail.	[82]
	Ziehl-Neelsen staining of the fecal smears, bursae of Fabricius, or respiratory organs of broilers revealed infection rates of 18.7% of <i>Cryptosporidium</i> species.	[16]
Scotland	<i>C. baileyi</i> was molecularly identified in wild red grouse with sinusitis, conjunctivitis, and swollen head.	[105]
	<i>C. galli</i> was isolated from the stomach of hens and it was transmitted from hens to chickens.	[48]
The Czech Republic	<i>C. baileyi</i> was identified in 15 out of the 22 avian-derived isolates, while <i>C. meleagridis</i> was identified in 5 avian-derived isolates. One isolate (B1-30), from a rose-ringed parakeet, exhibited a mixed infection of both <i>C. meleagridis</i> and <i>C. baileyi</i> .	[138]
Germany	<i>C. baileyi</i> was microscopically and molecularly identified from raptors and from a German falcon breeder with a history of respiratory distress.	[88]
England	<i>C. baileyi</i> was detected in red grouse moors with bulgy eye signs.	[108]
France	<i>C. baileyi</i> infection didn't prevent the induction of immunity against Marek's disease virus serotype 1 vaccine (CVI988/Rispens) in chickens.	[112]
Hungary	Chicken anemia virus infection may increase the reproductive potential of <i>C. baileyi</i> in chickens and both pathogens have synergistic effect on each other.	[113]
The Netherlands	<i>Cryptosporidium</i> infection was associated with colitis and cystitis in green iguanas. The disease was characterized by cloacal prolapses and cystitis. Based on molecular gene identification, <i>Cryptosporidium</i> species were c belonging to the intestinal <i>Cryptosporidium</i> lineage, but not to <i>C. saurophilum</i> or <i>C. serpentis</i> .	[63]
Denmark	In 73 of 128 ducklings, and in 44 of 74 goslings, <i>Cryptosporidium</i> species were detected. Tissues from the bursa of Fabricius were positive in both species of birds. The presence or absence of the parasite could not be correlated with clinical signs or lesions and/or poor performance of the birds.	[68]



**Table 1:** continuation

Poland	A total of 499 fecal dropping from 308 free-ranging, 90 captive, and 101 domestic birds were tested by conventional, immunological, and molecular techniques for <i>Cryptosporidium</i> . <i>C. parvum</i> was found in 19 (3.8%).	[93]
Greece	<i>C. baileyi</i> was molecularly identified in 7-week-old Saker falcon died with a history of severe respiratory signs and lesions and otitis media.	[107]
	Ziehl-Neelsen staining of the fecal smears, bursae of Fabricius, or respiratory organs of broilers showed infection rates (24.3%) of <i>Cryptosporidium</i> species.	[142]
South Africa	Heavy infection of the cloacal and bursal tissues with <i>Cryptosporidium</i> species was observed in ostriches showed phallus prolapse as well as in normal birds. Loss of the microvilli borders, epithelial hyperplasia, swelling of organelles, and nuclear changes were detected microscopically.	[84]
	The histological findings in emaciated 4-month-old ostriches revealed presence of <i>Cryptosporidium</i> species in the necrotic and inflamed pancreatic epithelium.	[127]
Nigeria	The total prevalence of <i>Cryptosporidium</i> oocysts was 7.4% in different avian species. Local birds had the highest prevalence rate (9.5%), followed by exotic birds (6.6%) and the wild ones (5.3%).	[4]
China	The infection rate of <i>Cryptosporidium</i> among broiler chicken was 10% (38/385). <i>C. baileyi</i> , <i>C. meleagridis</i> , and <i>Cryptosporidium</i> avian genotype II were molecularly identified.	[25]
	The overall infection rate of <i>Cryptosporidium</i> was 10.6% (163/1542) in layer chickens, 3.4% (16/473) in broilers, and 16.3% (92/564) in Pekin ducks. <i>C. baileyi</i> (184/187) on chicken and duck farms, and <i>C. meleagridis</i> (3/187) on layer chicken farms were detected.	[28]
	<i>C. baileyi</i> (33/471; 7.0%) and <i>C. meleagridis</i> (15/471; 3.2%) were identified in broiler chickens. Two subtypes of <i>C. meleagridis</i> including IIIbA26G1R1b and IIIbA22G1R1c were characterized.	[27]
	The overall prevalence of <i>Cryptosporidium</i> in psittacine birds was 8.1% (35/434). Three <i>Cryptosporidium</i> species and two genotypes were identified, including <i>C. baileyi</i> (18/35 or 51.4%) in red-billed leiothrixes, white Java sparrows, common mynas, zebra finches, a crested Lark, a Gouldian finch, and a black-billed magpie; <i>C. meleagridis</i> (3/35 or 8.6%) in a Bohemian waxwing, a Rufous turtle dove, and a fan-tailed pigeon; <i>C. galli</i> (5/35 or 14.3%) in Bohemian waxwings and a silver-eared Mesia; <i>Cryptosporidium</i> avian genotype III (3/35 or 8.6%) in cockatiels and a red-billed blue magpie; and <i>Cryptosporidium</i> avian genotype V (6/35 or 17.1%) in cockatiels.	[59]
	The overall prevalence of <i>Cryptosporidium</i> infection in pigeons was 0.82% (2/244). <i>C. baileyi</i> and <i>C. meleagridis</i> were identified.	[74]
	The overall prevalence of <i>Cryptosporidium</i> in quail was 13.1% (29 of 47 farms). The highest prevalence was observed in autumn and the lowest in winter. <i>C. baileyi</i> and <i>C. meleagridis</i> were molecularly detected.	[78]
	<i>C. baileyi</i> infection in baby chicks may induce bursal atrophy, immunosuppressive effects against avian influenza (H5N1), and increase the susceptibility to the virus.	[121]
	A total of 303 fecal samples were collected from ostriches and 31 samples (10.2%) were <i>Cryptosporidium</i> -positive upon microscopic analysis. The infection rate was 27.6% in ostriches aged 16-60 days, 1.2% in those aged 61-180 days, and 20.4% in those aged >10 years. Genetic analysis of the isolated parasite revealed presence of <i>C. muris</i> and <i>C. baileyi</i> .	[137]
	Eleven <i>Cryptosporidium</i> isolates were identified molecularly in cockatiels. Three new genotypes in <i>C. meleagridis</i> , avian genotype III, and a new avian genotype V were characterized.	[52]
	<i>Cryptosporidium</i> avian genotype III was molecularly identified in peach-faced lovebirds.	[58]
Japan	Mixed infection with <i>Mycoplasma gallisepticum</i> and <i>Cryptosporidium</i> species or other bacteria was detected in Japanese quail. Birds showed swelling of the head, nasal discharge, increased lacrimation, decreased egg production, mortality rate of 5.7% per day, caseous exudate in the sinuses, egg peritonitis, and airsacculitis. Microscopically, non-purulent or purulent inflammation accompanied by lymphoid hyperplastic tissue with germinal centers were observed in the oculo-facial respiratory mucosa.	[77]
Korea	Infection with <i>C. baileyi</i> induced an immunosuppressive effect on Newcastle disease virus vaccine in 2-day-old chicks and the infection with the parasite may increase the susceptibility to this virus infection.	[118]
	<i>C. baileyi</i> infection could suppress the immune response against infectious bronchitis virus vaccine and perhaps increase the susceptibility to this virus infection in chickens.	[120]

**Table 1:** continuation

Malaysia	A total of 90 samples were screened for <i>Cryptosporidium</i> from different avian species. Phylogenetic trees identified all the isolates as <i>C. parvum</i> .	[94]
Bangladesh	Microscopic examination revealed presence of <i>Cryptosporidium</i> species in 19.8% (39/197) of avian specimens. Molecular characterization showed that 15.7% (31/197) of the samples were <i>Cryptosporidium</i> positive. Of these 31 samples, 17 were <i>C. baileyi</i> (8.7%), 12 were <i>C. meleagridis</i> (6.0%), and 2 were <i>C. parvum</i> (1.0%). <i>C. meleagridis</i> had two subtypes (IIIbA21G1R1 and IIIbA23G1R1), which were found in broiler, native and sonali chickens, and a pigeon. Two novel subtypes (IIIbA21G2R1 and IIIbA20G2R1) were identified in sonali chickens, a broiler chicken, and a layer chicken.	[37]
Vietnam	<i>C. baileyi</i> genotype II was detected in 2-3-month-old ostriches with a prevalence rate of 23.7% (110 out of 464 samples).	[57]
Thailand	<i>C. meleagridis</i> was identified in pigeons, however, <i>Cryptosporidium</i> avian genotype III was detected in seagulls.	[73]
Egypt	The prevalence rates of <i>C. meleagridis</i> , <i>C. baileyi</i> , and <i>C. galli</i> were 30.8% in bobwhite quails and 33.3% in brown quails with a total percentage of 31.9%.	[49]
	<i>Cryptosporidium</i> showed less incidence in ducks in autumn (2.4%) and summer (3.2%) and in turkeys (4.4%).	[50]
	The incidence of <i>Cryptosporidium</i> species in ducks was 39.9%, with the highest rate in winter (74.6%) and the lowest rate in autumn (7.1%). Approximately 55% of 100 ducks had antibodies against the parasite.	[51]
	<i>C. baileyi</i> could be one cause of vaccination failure against Newcastle disease and/or avian influenza viruses in chicken's farms.	[119]
Iran	<i>Cryptosporidium</i> species were identified in pigeons with overall prevalence rate of 2.94%.	[72]
	<i>C. meleagridis</i> was histologically detected in the intestinal tract of turkey poults suffering from diarrhea and unthriftiness. The oocyst shedding was detected only in 29% of positive birds.	[96]
	Microscopic examination of the intestine and trachea demonstrated that 23.75% of 240 broiler samples were infected	[148]
	<i>Cryptosporidium</i> infection rates were 34% and 44% in chickens and turkeys, respectively, with all positive turkeys (25) and most positive chickens (26/31) having <i>C. meleagridis</i> . All <i>C. meleagridis</i> isolates belonged to a new subtype family.	[24]
Algeria	A total of 345 faecal samples were collected from domestic, captive, and wild birds. <i>Cryptosporidium</i> species were detected in 31 samples. Sequence analysis revealed the presence of <i>C. baileyi</i> in domestic chicken broilers, captive ostriches, and a wild mallard, and <i>C. meleagridis</i> in a graylag goose, chickens, and turkeys. The overall prevalence of <i>Cryptosporidium</i> in chickens and turkeys was 2% and 6%, respectively. Both <i>C. meleagridis</i> and <i>C. baileyi</i> were detected in chicken broilers, with a prevalence ranging from 9% to 69%. Turkeys were positive only for <i>C. meleagridis</i> , with a 13% prevalence at the animal level. Subtyping of <i>C. meleagridis</i> isolates showed subtype IIIgA22G3R1 in graylag goose and chicken broilers and IIIgA23G2R1 in chicken and turkey broilers.	[29]
Morocco	Examination of intestine, bursa of Fabricius, and trachea revealed existence of <i>Cryptosporidium</i> species in 37% of 225 broilers flocks. The prevalence of infection within flocks varied from 14%-100%. High incidence of <i>Cryptosporidium</i> infection occurred in 36-45-day-old broilers (52%). <i>Cryptosporidium</i> species were detected in bursa (24%), intestine (15%), and trachea (2%). In the bursa of Fabricius, <i>Cryptosporidium</i> -induced epithelial lesions, lymphoid atrophy, and depletion.	[143]
Tunisia	<i>Cryptosporidium</i> was detected in 9 out of 200 broiler chicken (4.5%). Molecular characterization showed presence of <i>C. meleagridis</i> in one broiler chicken.	[144]
Turkey	Clinical signs of cryptosporidiosis in 10-day-old pigeon were depression, ruffled feathers, and diarrhea. Gross lesions were mild hyperaemic segments of small intestine distended with typical green watery ingesta. <i>Cryptosporidium</i> species were found in the villi of lower portions of atrophic and misshapen small intestine.	[70]
Dubai	<i>C. parvum</i> was molecularly detected from an outbreak of catarrhal enteritis and mortality among stone curlews.	[132]

## Susceptibility and infection

Cryptosporidiosis has been recorded worldwide in more than 30 species of domestic, wild, and captive birds (23). The disease was demonstrated in chickens, turkeys, ducks, geese, quails, pheasants, ostriches, partridges, and peacocks (65-67, 1).

In water fowl (ducks and geese), Richter et al. (68) detected the presence of *Cryptosporidium* species in the intestinal and respiratory tracts of ducklings and goslings at incidence rates of 57% and 59%, respectively, using indirect immunofluorescence assay. Experimentally, *C. baileyi* was identified in ducks in Brazil (36). However, *C. baileyi* was detected using the in situ hybridization technique in the conjunctival and bursal tissues of geese experimentally infected with Usutu virus (33).

Moreover, *C. baileyi* and *C. meleagridis* could infect the intestine, bursa, and cloaca of ducks after the incubation period up to 9-10 days (69).

In pigeons, cryptosporidiosis has been identified by some researchers (70, 71). Qi et al. (59) identified *C. meleagridis* in one pigeon using molecular techniques, while Radfar et al. (72) found that the prevalence rate of *Cryptosporidium* species was 3.4% in adult pigeons and 2.3% in squabs. Moreover, cryptosporidiosis infection has been microscopically and molecularly identified in different countries like Thailand (73), China (74), and Brazil (75).

In Australia, quails gain natural infection with *Cryptosporidium* species like *C. baileyi* and *C. meleagridis* (76, 39). The natural infection of quails with *C. baileyi* has been recorded in Japan using molecular techniques (77). Both *C. baileyi* and *C. meleagridis* were molecularly characterized in China (78). The experimental infection of quails with *C. baileyi* isolates of chicken was first unsuccessful (6, 7), while Cardozo et al. (79) succeeded in the induction of infection in quails using isolates of broiler chickens.

Infection with *C. meleagridis* has also been reported in red-legged partridge chicks (10).

Ratite bird species also showed susceptibility to cryptosporidiosis. The first detection of *Cryptosporidium* infections in ostriches was in the 1990s (80, 8, 81-84). Gajadhar (81) identified *Cryptosporidium* in the feces of 14/165 (8.5%) African ostriches. However, in 1994, Gajadhar (82) investigated these oocysts and the host specificity. The identified oocysts were identical

to *C. meleagridis*, but they were non-infectious to chickens, turkeys, quails, and mice (82). Later on, Ponce Gordo et al. (85) identified *Cryptosporidium* oocysts in 2-month-old to 5-year-old ostriches, but with a low prevalence rate (2/336, 0.6 %). Microscopically, the prevalence rate of *C. baileyi* in Europe was 60% in adult ostriches and rheas (85), and that of the Brazilian isolate was 44% in adult ostriches (86). *Cryptosporidium* avian genotype II species was molecularly identified in ostriches (56, 41), which was similar to the Brazilian isolate of *C. baileyi* (9). In Vietnam, Nguyen et al. (57) identified *Cryptosporidium* avian genotype II oocysts of *C. baileyi* in 2-3-month-old ostriches with a prevalence rate of 23.7% (110 out of 464 samples).

Pet birds could be infected with *C. galli*, *C. meleagridis*, and *C. baileyi*. These species have been described as important zoonotic parasites to humans, especially kids (87). In addition, *C. baileyi* has been isolated from the upper respiratory tracts of three mixed-bred falcons (88). In owls, Molina-Lopez et al. (89) reported an infection with *C. baileyi* associated with an outbreak of ocular and respiratory diseases. *C. galli* and novel *Cryptosporidium* avian genotype VI have been found in North American red-winged blackbirds (90).

The age group susceptibility to cryptosporidiosis is variable according to the *Cryptosporidium* species. It has been proposed that young birds are the most important risk group since their immune system is not yet fully developed (43). The infection rate of *Cryptosporidium* was 4.9% in 1-20-day-old broiler chickens, 24.6% in 31-60-day-old layer chickens, and 40.3% in 11-30-day-old Peking ducks (28). Moreover, it has been shown that chickens of all ages are susceptible to *C. baileyi*, while 31-120-day-old layer chickens are more susceptible to *C. meleagridis* infection (28). In addition, *C. baileyi* and *C. meleagridis* were detected in chicken aged above four months (27). In the United States, the infection is predominant in 4-9-week-old turkeys (43). In the study of Helmy et al. (20), infections with *Cryptosporidium* were noted in 13.8% of 13-20-week-old turkeys, 5.7% of 1-6-week-old broilers, and 8.3% of layer chickens above 20 weeks of age.

Perhaps broiler chickens act as a source of cryptosporidiosis disease infection and transmission of oocysts (91). Birds are infected with *Cryptosporidium* by ingestion or inhalation of sporulated oocysts in contaminated litter, feces,



water, and dust. The main route of *Cryptosporidium* transmission is the fecal-oral route as oocysts are shed in the droppings, contaminate the soil and water, and thus provide many paths into the food chain (92). Mechanical transmission through migratory birds has also been reported. Although these birds have a low level of *Cryptosporidium* infections, they shed oocysts and contaminate the environment (93). Moreover, asymptomatic birds act as a mechanical source of transmission of infective oocysts to other birds, animals, and humans (94). Poor hygienic measures are associated with increased incidence of the infection in poultry flocks (15).

### Clinical picture

The severity of *Cryptosporidium* clinical disease in poultry depends on birds' hygienic conditions, stocking density, crowding, and mixing of different ages and species of birds (15). Intestinal *Cryptosporidium* infection is characterized by diarrhea, lowered weight gain, and distention of the intestinal lumen with mucus and gases, in addition to the presence of different stages of *Cryptosporidium* in different parts of the small intestine (95, 96).

Infection of turkeys with *C. meleagridis* presents either subclinically (97, 98) or clinically in the form of enteritis (22, 95, 99). *C. meleagridis* may infect chickens (69) with intestinal involvement.

It has been shown that *C. baileyi* mainly affects the respiratory and intestinal tracts of poultry (38, 40). Reports of *C. baileyi* respiratory tract infections have been detected in chickens (31), turkeys (100), ducks (101, 102), geese (33), and pheasants (103). In addition, some wild birds, such as falcons, owls, swallows, and the red grouse, showed infection of the upper respiratory system, middle ear, and eyes with *C. baileyi* (104, 88, 89;105-108). Co-infection of *C. baileyi* with *Escherichia coli* and infectious bronchitis (IB) virus was reported, and the affected birds showed mortality associated with lower respiratory tract infections, such as bronchitis, pneumonia, and air sacculitis (109-111). Moreover, *C. baileyi* is associated with other causative agents with high mortality and lowered body weight gain. Among these infectious agents are the virus vaccine of Marek's disease (MD) (Rispen) (112), chicken infectious anemia virus (113), infectious bursal disease (IBD) virus (114), and reoviruses (115).

In addition, it has been reported that *C. baileyi* induces humoral immuno-suppression effect through the infection of the bursa of Fabricius (116). This effect is controversial and shows different results. For example, the infection of chickens with *C. baileyi* suppresses the immune response to the virus vaccines of MD (117, 112), IBD (114), reoviruses (115), Newcastle disease (118, 119), IB disease (120), and avian influenza disease (121, 119). Although the experimental challenges of chickens with *C. baileyi* induced purulent bursitis and hyperplasia as well as slight lymphoid atrophy (122, 123), no effect on the humoral immune response has been detected (110, 123).

Severe sinusitis with a morbidity rate of 5%-10% was observed in young turkey poults infected with *Mycoplasma* species (100). Respiratory signs were observed in thirteen turkeys that were histologically positive for *Cryptosporidium* species (124). However, a history of self-limiting diarrhea was identified in a flock of turkey poults suffering from invasive *Cryptosporidium* (95). In Iran, *C. meleagridis* oocysts were detected in diarrheic unthrifty turkey poults (96). Sneezing, frothy eyes, swollen sinuses, coughing, and rattling were reported in a case of *C. baileyi* and *C. meleagridis* infections in turkeys (125).

*Cryptosporidium* species were detected in five-day-old quails with high mortality (6). Ritter et al. (7) reported a mortality rate up to 45% that was associated with acute fatal diarrhea in 1-17-day-old quails as the infection was associated with *Cryptosporidium* and reovirus. A similar study was carried out by Guy et al. (126) who observed severe diarrhea and mortality as well as high oocyst shedding after the experimental coinfection of quails with *Cryptosporidium* and reovirus. Respiratory signs and lesions, drop in egg production with peritonitis, and a daily mortality rate of 5.7% were reported in Japanese quails due to mixed infection with *Mycoplasma gallisepticum* and *Cryptosporidium* species (77). However, in a study of Wang et al. (78) in China, no signs were detected in a *Cryptosporidium*-positive quail flock.

In pigeons, invasive stages of *Cryptosporidium* were identified in the intestine of a pigeon with depression, and diarrhea soiled the feather around the vent (70). Moreover, yellow watery diarrhea, weight loss, and dehydration were associated with 40% morbidity and 5% mortality rates (71).

Diarrhea, cough, morbidity rates of 60-70%, and a mortality rate more than 50% were reported

in red-legged partridge chicks having mixed infection with *C. meleagridis* and *C. baileyi* (10).

In ostriches, prolapsed cloacae, recta, and bursae were observed in dead 4-week-old chicks heavily infected with *Cryptosporidium* (8, 83, 84). Moreover, it has been proposed that *Cryptosporidium* infection is associated with pancreatic necrosis (80, 127). Infected 7-30-day-old ostrich chicks with *Cryptosporidium* genotype II showed sudden death with cloacal prolapse, and the oocysts were identified in the rectum, coprodeum, urodeum, and bursa (9).

Pet birds like budgerigars (128), cockatiels (128, 129), parrots (130), and lovebirds (131) exhibited intestinal cryptosporidiosis with high mortality.

When *C. parvum* or *C. galli* infects chickens or turkeys, no clinical signs could be detected (14, 43). However, in Dubai, an outbreak of catarrhal enteritis and mortality were reported among stone curlews (132). Birds infected with gastric *C. galli* showed diarrhea, weight loss, and sometimes mortality (46, 133, 39). Chronic proventriculitis is associated with *C. galli* with secondary infections (134, 135). In psittacine birds, strains of *C. galli* genotype III induced chronic vomiting, weight loss, and proventriculitis (58, 136).

Other species, *C. muris* and *C. andersoni*, were found in birds' droppings perhaps due to mechanical transmission from mammals (41). In China, adult ostriches showed infection with *C. muris* (137). In the Czech Republic, a novel genotype of *Cryptosporidium* (Eurasian woodcock) was molecularly identified, and it caused proventriculus and death of Eurasian woodcock species of birds (138).

### The life cycle of *Cryptosporidium*

The shed oocysts are usually present in high numbers, resist the environmental conditions, and do not require special conditions for maturation. Infection with infective oocysts through ingestion is followed by excitation in the small intestine with the release of sporozoites. Released sporozoites proliferate in the intestinal epithelial cells where the asexual multiplication phase begins. As a result of asexual multiplication, invasion of merozoites to the neighboring cells is followed by the sexual multiplication phase. After this stage, production of macrogamonts and microgamonts

occurs, followed by fertilization of macrogamonts and production of oocysts that sporulate in the host before shedding. The sporulated oocysts containing four sporozoites are shed in feces and respiratory secretions (especially in birds and children) in case of respiratory cryptosporidiosis (139, 140).

### Laboratory diagnosis

Various methods including microscopic, immunological, and molecular techniques are used for the detection of *Cryptosporidium* infection (Figure 1). Microscopic examination includes concentration flotation and sedimentation techniques. Fecal samples that were concentrated using Sheather's sugar flotation technique followed by bright-field microscopy showed overall infections rates of *Cryptosporidium* of 3.4% in broilers and 10.6% in layer chickens in China (28). Iodine-saline wet mount method is another method for microscopic examination. However, routine fecal examination methods have some disadvantages like difficulties in distinguishing *Cryptosporidium* oocysts from other small debris particles, molds, algae, or yeasts (141).

Ziehl-Neelsen staining of the fecal smears, bursae of Fabricius, or respiratory organs of broilers revealed infection rates of *Cryptosporidium* of 18.7% in Scotland (16), 24.3% in Greece (142), 37% in Morocco (143), and 4.5% in Tunisia (144). In acid-fast stained smears, *Cryptosporidium* oocysts appear as pink to red and spherical to ovoid bodies with a blue or purple background. This technique is useful in smears with a high number of oocysts or even a low number until one oocyst and can be stored permanently for a long time (145). For the detection of oocysts in smears, the sensitivity was 67.5% for modified acid-fast staining and 53.75% for Giemsa staining (146). In Japan, the histological examination of tissues detected 36.8% of *Cryptosporidium* in broilers and 33.3% in layers (147). However, in Iran, this rate was 23.8% in broilers (148).

Flow cytometry is also used for the demonstration of *Cryptosporidium* after staining with fluorescent markers (149).

*Cryptosporidium* antigens can be detected through many immuno-chromatographic dipstick tests, enzyme immunoassays, reverse passive hemagglutination tests, and immunofluorescence

techniques (150-152). Some Egyptian studies used enzyme linked immunosorbent assay (ELISA) for the detection of antibodies against *Cryptosporidium* species in humans. For example, Gabr et al. (146) noted that the sensitivity of ELISA was 90% for the detection of cryptosporidiosis. In addition, Hassanein et al. (153) used this assay for the demonstration of *C. parvum* immunoglobulin G in the serum of Egyptian children with persistent diarrhea and acute lymphoblastic leukemia. Nanogold-beads-based ELISA was used for the detection of *Cryptosporidium* in the stool samples of diarrheic patients in Benha Province, Egypt. However, in an animal study, Fereig et al. (154) reported marked sero-prevalence of *C. parvum* in cattle in South Egypt using ELISA. A similar study was recently conducted in Japan, where the indirect ELISA showed total sero-positivity of 96.3% for *C. parvum* in cattle (155).

Unfortunately, the most common diagnostic traditional tools such as microscopy and immunology cannot discriminate *Cryptosporidium* species or subtypes to understand the transmission pathways and dynamics in humans (156). In addition, these tools have a much lower sensitivity than polymerase chain reaction (PCR) (17, 18). Accordingly, genotyping and subtyping of *Cryptosporidium* were done using restriction fragment length polymorphism (RFLP) analysis of the 18S rRNA gene (157, 158) and *Cryptosporidium* oocyst wall protein (COWP) gene (159) and sequence analysis of the 60-kDa glycoprotein gene (160). There are differences in the prevalence and infection rates according to the method used to detect *Cryptosporidium* (e.g., microscopic examination vs. PCR) (161, 156). The first molecular report regarding the genotyping and subtyping of *Cryptosporidium* in calves in Kafr El Sheikh Province, Egypt, was made by Amer et al. (162). They sequenced the SSU rDNA gene and COWP gene of *C. parvum* as well as the high polymorphic 60-kDa glycoprotein gene. In Beni-Suef Province, Egypt, Ibrahim et al. (163) identified *C. parvum* in cattle and buffaloes as well as *C. hominis* and *C. parvum* in humans using RFLP analysis of the COWP fragments. Moreover, the sequence analysis of the gp60 gene showed the *C. parvum* IIdA20G1 subtype in animals and humans. Helmy et al. (18) demonstrated through molecular techniques that the prevalence rate of cryptosporidiosis among 165 diarrheal chil-

dren in Ismailia Province was 49.1% (60.5% *C. hominis* and 38.3% *C. parvum*). Other molecular techniques such as fluorescence in situ hybridization (FISH) and loop-mediated isothermal amplification (LAMP), a nucleic acid amplification method, are used for the molecular detection of *Cryptosporidium* species (164, 165).

Few studies were done on different avian species regarding the molecular characterization of *Cryptosporidium* (36, 43, 55, 28, 15, 24). In Algeria, the PCR analysis of the intestine showed prevalence rates of *C. meleagridis* of 34% (26/90) and 44% (25/57) in the intestines of chickens and turkeys, respectively (24). However, *C. parvum* DNA was detected in feces in 86% of the chickens in Brazil using PCR (15). In Germany, Helmy et al. (20) demonstrated that the PCR analysis of chickens and turkeys' fecal specimens revealed an overall 7.0% prevalence rate of *C. parvum*, while in China, the prevalence was 10% in 90-day-old broiler chickens (25).

## Zoonotic importance

*Cryptosporidium* species in humans are regarded as one of the most infectious zoonotic protozoan parasites since 1976 during an outbreak of cryptosporidiosis in the United States due to contamination of water (166). The different routes of cryptosporidiosis transmission to humans are listed in Table 2.

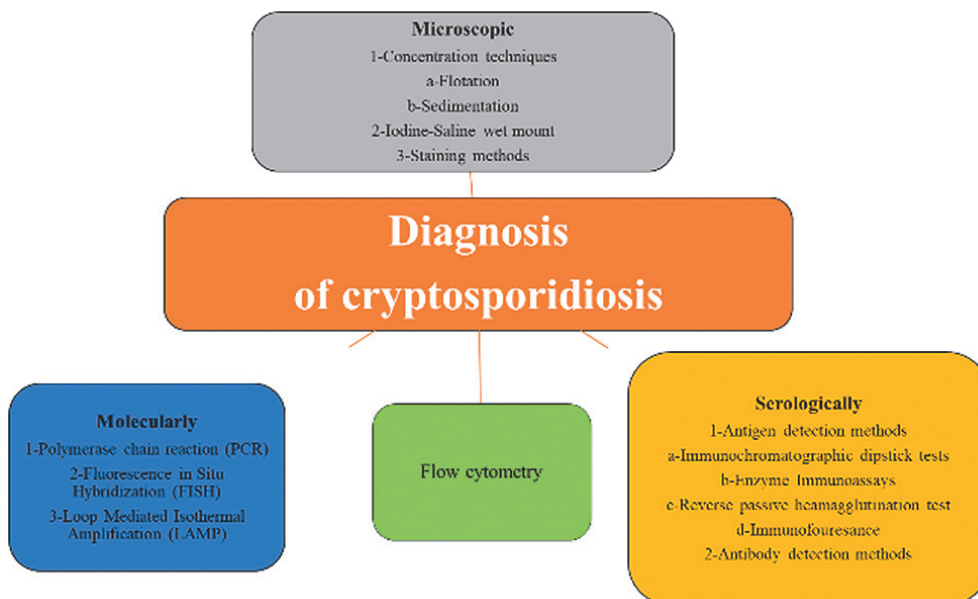
Humans can be infected with cryptosporidiosis predominantly through the consumption of contaminated food or water with infective oocysts or through direct contact with infected animals (167-169). Amer et al. (19) found that the dominant genotypes IIa and IId of *C. parvum* in Egyptians which were similar to those in contact calves suggests calves can be potential reservoirs of zoonotic cryptosporidiosis. Some outbreaks have been reported among veterinary students as a result of contact with animals (168-171). Birds are considered an important source of infection as they are mechanical disseminators and shedders of oocysts for long distances in the environment (172, 54, 173, 93, 55, 174, 20). Moreover, infection of pigeon handlers with *C. meleagridis* in China has been reported (74). Workers in farms that handle with birds can contaminate water, feed, or litter in the poultry houses with *Cryptosporidium* oocysts of mammalian/human origin (37). Pet birds are also regarded as an important source of infection



to humans (87), but the literature related to this point is very rare. Traveling, living in villages, drinking underground water (lakes, etc.), and contact with animals are risk factors associated with human cryptosporidiosis (18, 175).

Individuals can get infection of the gastrointestinal tract through different *Cryptosporidium* species. Cryptosporidiosis can affect immunocompetent HIV-infected individuals, children, and healthy persons, causing asymptomatic carrier status or severe lethal diarrhea (176). Previously, *C. parvum* in ruminants was the only cause of human cryptosporidiosis for many years (177), while *C. hominis* was not recognized as a separate species till 2002 (178). Nowadays, both *C. parvum* and *C. hominis* cause more than 90% of human infection, while other species or genotypes of animal origin can cause sporadic infection. Meanwhile, *C. meleagridis* is the only avian species with public health concern and causes zoonotic infection of humans (179, 25, 26). Xiao (180) stated that *C. meleagridis* is the third most common species causing a serious public health hazard in humans as it has a wider host spectrum. Two subtypes of *C. meleagridis* detected in AIDS patients were shared by chicken, ducks, and pigeons in the same location in Peru (25, 26). *C. meleagridis* was reported to be similar to *C. parvum* as both were responsible for 10%-20% of human cryptosporidiosis (181-184). In Bangladesh, in urban regions, the prevalence rate of *C. meleagridis* was 13%, which was more than *C. parvum* with a prevalence rate of 2% in children without diarrhea.

However, in rural regions, the prevalence rates of *C. meleagridis* and *C. parvum* were 90% and 4%, respectively, causing subclinical cryptosporidiosis (185). Stensvold et al. (186) and Wang et al. (26) demonstrated that the phylogenetic analysis of multiple loci of *C. meleagridis* isolates showed that these isolates may be related to those in humans, and that constitutes evidence of human infection by *C. meleagridis*. Furthermore, in Sweden, *C. meleagridis* isolates of layer and broiler chickens were found to be identical in nucleotide sequences (18S rRNA and HSP-70 genes) to isolates of human origin (91). Perhaps, this may be due to the anthrozoönotic nature of cryptosporidiosis as it is transmitted from chickens kept in households to the person in contact (187). It is important to note that a reverse zoonotic transmission (zooanthroponosis, from humans to animals) of *C. parvum* has also been reported (188). In addition, cryptosporidiosis is regarded as a largely anthroponotic disease that is transmitted from person to person, especially *C. hominis* or *C. parvum* (189). Cryptosporidiosis in humans is regarded as an acute life-threatening disease especially in immunocompetent hosts (179). It is characterized by the sudden onset of clinical signs a week after infection in the form of prolonged and persistent diarrhea. Severe infection can be seen in very young, malnourished, and immunocompromised persons. It has been documented that cryptosporidiosis is a major cause of mortality in infants and children under two years of age



**Figure 1:** Methods of diagnosis of cryptosporidiosis



**Table 2:** Transmission methods of cryptosporidiosis in humans in developing countries (190).

Source of infection	Reference (s)
Food and water contamination	[168, 169]
Livestock animals	[20, 167]
Calves	[19, 170, 171, 177]
Domestic poultry (chickens and turkeys)	[20, 25, 26, 37, 93, 172, 179, 187]
Pigeons	[70, 74]
Geese	[54]
Captive pet birds	[55, 87]
Free range birds (mallard duck, graylag goose, common merganser, mute swan, grey heron, white stork, carrion crow, and rook)	[93]
Aquatic birds (ducks, geese, coots, and cormorants)	strain (201). [174]

In Egypt, the prevalence rate of *Cryptosporidium* infection varies according to the locality. For example, Gabr et al. (191) demonstrated that *Cryptosporidium* infection was prevalent in diarrheic persons in Minia Province, as they showed that the overall prevalence rate of infection in 300 stained fecal samples was 44.7%. However, a previous study conducted by Gabr et al. (146) found that the prevalence rate was 61%. In immunocompetent and immunosuppressed children in Minia Province, the prevalence rates of *Cryptosporidium* infection were 42.2% and 60.2%, respectively (192). In another study conducted in Ismailia Province, the overall prevalence rate of *Cryptosporidium* species in humans was 49.1%, of which 60.5% were *C. hominis*, 38.2% were *C. parvum*, and 1.2% were *C. parvum* and *C. bovis* (193). In other provinces of Egypt, the prevalence rates were 23.5% in Abou El-Rish Hospital using nanogold-beads-based ELISA (194), 31.1% in Greater Cairo after staining of stool samples (195), 19.5% in Benha using microscopical and immunological techniques (196), 15% in Zagazig among chronic renal failure patients after conducting microscopical staining examination (197), and 33.3% in Ismailia among children (198). Moreover, ELISA results revealed that the incidences of *Cryptosporidium* were 37.7% and 91% in immunodeficient children and adult patients with cancer, respectively (199). In addition, the study of Antonios et al. (200) revealed that the prevalence rate of *Cryptosporidium* species among immunocompromised Egyptians was 33.3%.

The differences in the infection rates may depend on the immune status of individuals, age of the host, environmental habitats, season, sample size, and the virulence of the parasite

### Prevention and control

Elimination of *Cryptosporidium* infection through the destruction of the parasite is difficult perhaps due to the resistant and persistent nature of the oocysts as well as the wide distribution of the infection (202). Household hygiene practices are recommended to prevent transmission of the different *Cryptosporidium* species causing infection with cryptosporidiosis (203). Hygienic measures include regular and thorough cleaning and disinfection of birds' drinkers, feeders, cages, and premises, in addition to keeping separate cloths during contact with birds and washing hands with disinfectants before and after contact with the birds (67, 9, 135). A concentration of 6% or 7.5% hydrogen peroxide, chlorine dioxide, ozone, and ultraviolet light have been found to inactivate oocysts (204). Moreover, aluminum sulfate, iron sulfate, and iron chloride can coagulate oocysts present in water (205). In addition, reverse osmosis, filtration, and electronic/radiation methods have been used to counteract oocysts (206, 207). Halofuginone showed variable efficiency against cryptosporidiosis in animals (208, 23, 209). Lately, Hassan et al. (210) demonstrated the effect of silver nanoparticles as a water disinfectant against *C. parvum*, as oocysts showed considerable resistance to the traditional water treatment processes. Silver nanoparticles in a concentration of 1 ppm for 30 min and 0.1 ppm for 1 hr reduced oocysts by 97.2% and 94.4%, respectively.

Until now, there is no specific treatment of cryptosporidiosis in animals and humans. However, the United States Food and Drug Adminis-

tration (FDA) licensed and approved treatment of the infection with nitazoxanide after a trial conducted on mice (211). Nitazoxanide treated diarrhea in buffaloes within three to four days and reduced the shedding of oocysts (212). In humans, this treatment is recommended especially for patients aged one year or older in good health condition and with immune status (213, 214). Treatment with other drugs such as paromomycin, spiramycin, rifaximin, and azithromycin is unsatisfactory or inconsistent (215). Nutritional and supportive therapy is very important for complete recovery. Oral fluids and electrolyte replacement using sodium, potassium, bicarbonate, and glucose as well as starch-based oral rehydration solutions can provide calories with lower osmolarity, which can help in restoring mucosal function, enhance immune responses, and help rehabilitate the intestinal mucosal barrier following mucosal injury.

Due to the development of drug resistance, there is a demand to search for alternatives to control cryptosporidiosis. Some studies were conducted to evaluate the effect of using different herbs and their extracts on controlling cryptosporidiosis (216). Oil extracts can be effective in the complete elimination of oocyst shedding on the ninth day postinfection (217). The anti-cryptosporidiosis effects of pine-bark, garlic, onion, cinnamon, blueberry, and curcumin extracts showed successful results (218-222, 212). In chickens, Wahba et al. (219) demonstrated that garlic extract induced a mild reduction in *C. baileyi* oocyst shedding in experimentally infected birds, but there was a significant difference with control non-treated birds. However, both garlic and nitazoxanide completely eradicated *Cryptosporidium* oocyst shedding in the treated buffaloes (212). Moreover, black seeds or black cumin (*Nigella sativa*) can be used for the treatment of *C. parvum* in experimentally infected calves (223). Zaki and El-Amir (224) stated that phenyl vinyl sulfone (cysteine protease inhibitor) with black seeds altered *Cryptosporidium* oocyst shedding compared with paromomycin treatment in mice. Another recent Egyptian study conducted by Sadek et al. (225) showed that both garlic and black seed extracts were greatly effective in reducing *Cryptosporidium* oocyst excretions in mice (75.4%) compared with treatment with nitazoxanide. Interestingly, after the treatment of cryptosporidiosis HIV patients with high doses

of garlic, some patients showed recovery from chronic diarrhea and complete healing (226).

In conclusion, cryptosporidiosis is considered an important disease in animals and birds as it induces severe economic losses, in addition to the public health significance of the disease in humans. Therefore, several studies, especially in developing countries, should be conducted on cryptosporidiosis infection in various hosts and its relation with humans.

### Conflict of interests

No conflict of interests is declared.

### References

1. Ryan U. *Cryptosporidium* in birds, fish and amphibians. *Exp Parasitol* 2010; 124: 113–20. DOI: 10.1016/j.exppara.2009.02.002
2. Bodager JR, Parsons MB, Wright PC, et al. Complex epidemiology and zoonotic potential for *Cryptosporidium suis* in rural Madagascar. *Vet Parasitol* 2015; 207: 140–3. DOI: 10.1016/j.vetpar.2014.11.013
3. Ryan U, Power M. *Cryptosporidium* species in Australian wildlife and domestic animals. *Parasitology* 2012; 139: 1673–88. DOI: 10.1017/S0031182012001151
4. Bamaiyi PH, Umoh JU, Abdu PA, Lawal IA. The prevalence of *Cryptosporidium* oocysts in birds in Zaria, Nigeria. *Borneo J Resour Sci Technol* 2013; 2: 52–9.
5. Inpankaew T, Jiyipong T, Wongpanit K, et al. Molecular detection of *Cryptosporidium* spp. infections in water buffaloes from northeast Thailand. *Trop Anim Health Prod* 2014; 46: 487–90. DOI: 10.1007/s11250-013-0499-8
6. Hoerr FJ, Current WL, Haynes TB. Fatal cryptosporidiosis in quail. *Avian Dis* 1986; 30: 421–5. DOI: 10.2307/1590550
7. Ritter GD, Ley DH, Levy M, Guy J, Barnes HJ. Intestinal cryptosporidiosis and reovirus isolation from bobwhite quail (*Colinus virginianus*) with enteritis. *Avian Dis* 1986; 30: 603–8. DOI: 10.2307/1590430
8. Bezuidenhout AJ, Penrith ML, Burger WP. Prolapse of the phallus and cloaca in the ostrich (*Struthio camelus*). *J S Afr Vet Assoc* 1993; 64: 156–8.
9. Santos MMAB, Peiro JR, Meireles MV. Cryp-

- tosporidium infection in ostriches (*Struthio camelus*) in Brazil: clinical, morphological and molecular studies. *Braz J Poult Sci* 2005; 7: 113–7. DOI: 10.1590/S1516-635X2005000200008
10. Pages-Mante A, Pages-Bosch M, Majo-Masferrer N, et al. An outbreak of disease associated with cryptosporidia on a red-legged partridge (*Alectoris rufa*) game farm. *Avian Pathol* 2007; 36: 275–8. DOI: 10.1080/03079450701439389
11. Nakamura AA, Meireles MV. Cryptosporidium infections in birds—a review. *Braz J Vet Parasitol* 2015; 24: 253–67. DOI: 10.1590/s1984-29612015063
12. McDougald LR. Cryptosporidiosis. In: Swayne DE, Glisson JR, McDougald LR, et al., eds. *Diseases of poultry*. 13th ed. Ames : Wiley-Blackwell, 2013: 1085–91.
13. Berrilli F, D’Alfonso R, Giangaspero A, et al. *Giardia duodenalis* genotypes and *Cryptosporidium* species in humans and domestic animals in Côte d’Ivoire: occurrence and evidence for environmental contamination. *Trans R Soc Trop Med Hyg* 2012; 106: 191–5. DOI: 10.1016/j.trstmh.2011.12.005
14. Ryan UM, Xiao L, Read C, et al. A redescription of *Cryptosporidium galli* Pavlasek, 1999 (Apicomplexa: Cryptosporidiidae) from birds. *J Parasitol* 2003a; 89: 809–13. DOI: 10.1645/ge-74ri
15. Bomfim TCB, Gomes RS, Huber F, Couto MCM. The importance of poultry in environmental dissemination of *Cryptosporidium* spp. *Open Vet Sci J* 2013; 7: 12–7. DOI: 10.2174/1874318801307010012
16. Randall CJ. Cryptosporidiosis of the bursa of fabricius and trachea in broilers. *Avian Pathol* 1982; 11: 95–102. DOI: 10.1080/03079458208436084
17. Helmy YA, Kruecken J, Noeckler K, von Samson-Himmelstjerna G, Zessin KH. Comparison between two commercially available serological tests and polymerase chain reaction in the diagnosis of *Cryptosporidium* in animals and diarrhoeic children. *Parasitol Res* 2014; 113: 211–6. DOI: 10.1007/s00436-013-3645-3
18. Helmy YA, von Samson-Himmelstjerna G, Noeckler K, Zessin KH. Frequencies and spatial distributions of *Cryptosporidium* in livestock animals and children in the Ismailia province of Egypt. *Epidemiol Infect* 2015; 143: 1208–18. DOI: 10.1017/s0950268814001824
19. Amer S, Zidan S, Adamu H, Ye J, Roellig D, et al. Prevalence and characterization of *Cryptosporidium* spp. in dairy cattle in Nile River delta provinces, Egypt. *Exp Parasitol* 2013; 135: 518–23. DOI: 10.1016/j.exppara.2013.09.002
20. Helmy YA, Krücken J, Abdelwhab EM, von Samson-Himmelstjerna G, Hafez HM. Molecular diagnosis and characterization of *Cryptosporidium* spp. in turkeys and chickens in Germany reveals evidence for previously undetected parasite species. *PLoS One* 2017; 12: e0177150. DOI: 10.1371/journal.pone.0177150
21. Tyzzer EE. Coccidiosis in gallinaceous birds. *Am J Hyg* 1929; 10: 269–83. DOI: 10.1093/oxfordjournals.aje.a112759
22. Slavin D. *Cryptosporidium meleagridis* (sp. nov.). *J Comp Pathol* 1955; 65: 262–6. doi: 10.1016/S0368-1742(55)80025-2
23. Sreter T, Kovacs G, da Silva AJ, et al. Morphologic host specificity and molecular characterization of a Hungarian *Cryptosporidium meleagridis* isolate. *Appl Environ Microbiol* 2000; 66: 735–8. DOI: 10.1128/AEM.66.2.735-738.2000
24. Baroudi D, Khelef D, Goucem R, et al. Common occurrence of zoonotic pathogen *Cryptosporidium meleagridis* in broiler chickens and turkeys in Algeria. *Vet Parasitol* 2013; 196: 334–40. DOI: 10.1016/j.vetpar.2013.02.022
25. Wang L, Xue X, Li J, et al. Cryptosporidiosis in broiler chickens in Zhejiang province, China: molecular characterization of oocysts detected in fecal samples. *Parasite* 2014a; 21: e36. DOI: 10.1051/parasite/2014035
26. Wang Y, Yang W, Cama V, et al. Population genetics of *Cryptosporidium meleagridis* in humans and birds: evidence for cross-species transmission. *Int J Parasitol* 2014b; 44: 515–21. DOI: 10.1016/j.ijpara.2014.03.003
27. Liao C, Wang T, Koehler AV, et al. Molecular investigation of *Cryptosporidium* in farmed chickens in Hubei province, China, identifies ‘zoonotic’ subtypes of *C. meleagridis*. *Parasit Vectors* 2018; 11: e484. DOI: 10.1186/s13071-018-3056-5
28. Wang R, Jian F, Sun Y, et al. Large-scale survey of *Cryptosporidium* spp. in chickens and Pekin ducks (*Anas platyrhynchos*) in Henan, China: prevalence and molecular characterization. *Avian Pathol* 2010; 39: 447–51. DOI: 10.1080/03079457.2010.518314
29. Laatamna AE, Holubova N, Sak B, Kvac M. *Cryptosporidium meleagridis* and *C. baileyi* (Apicomplexa) in domestic and wild birds in Algeria. *Folia Parasitol* 2017; 64: e018. DOI: 10.14411/



fp.2017.018

30. Current WL, Upton SJ, Haynes TB. The life cycle of *Cryptosporidium baileyi* n. sp. (Apicomplexa Cryptosporidiidae) infecting chickens. *J Protozool* 1986; 33: 289–96. DOI: 10.1111/j.1550-7408.1986.tb05608.x

31. Blagburn BL, Lindsay DS, Hoerr FJ, Davis JF, Giambrone JJ. Pathobiology of cryptosporidiosis (*C. baileyi*) in broiler chickens. *J Protozool* 1991; 38: 25S–8S.

32. Goodwin MA, Brown J, Resurreccion RS, Smith JA. Respiratory coccidiosis (*Cryptosporidium baileyi*) among northern Georgia broilers in one company. *Avian Dis* 1996; 40: 572–5. DOI: 10.2307/1592266

33. Chvala S, Fragner K, Hackl R, Hess M, Weissenböck H. Cryptosporidium infection in domestic geese (*Anser anser f. domestica*) detected by *in-situ* hybridization. *J Comp Pathol* 2006; 134: 211–8. DOI: 10.1016/j.jcpa.2005.11.002

34. Abbassi H, Coudert F, Cherel Y, et al. Renal cryptosporidiosis (*Cryptosporidium baileyi*) in specific-pathogen-free chickens experimentally coinfecting with Marek's disease virus. *Avian Dis* 1999; 43: 738–44. DOI: 10.2307/1592742

35. Trampel DW, Pepper TM, Blagburn BL. Urinary tract cryptosporidiosis in commercial laying hens. *Avian Dis* 2000; 44: 479–84. DOI: 10.2307/1592566

36. Huber F, da Silva S, Bomfim TC, Teixeira KR, Bello AR. Genotypic characterization and phylogenetic analysis of *Cryptosporidium* sp. from domestic animals in Brazil. *Vet Parasitol* 2007; 150: 65–74. DOI: 10.1016/j.vetpar.2007.08.018

37. Kabir MHB, Han Y, Lee S-H, et al. Prevalence and molecular characterization of *Cryptosporidium* species in poultry in Bangladesh. *One Health* 2020; 9: 100122. DOI: 10.1016/j.onehlt.2020.100122

38. O'Donoghue PJ. Cryptosporidium and cryptosporidiosis in man and animals. *Int J Parasitol* 1995; 25: 139–95. doi: 10.1016/0020-7519(94)e0059-v

39. Morgan UM, Monis PT, Xiao L, et al. Molecular and phylogenetic characterisation of *Cryptosporidium* from birds. *Int J Parasitol* 2001; 31: 289–96. doi: 10.1016/s0020-7519(00)00164-8

40. Ramirez NE, Ward LA, Sreevatsan S. A review of the biology and epidemiology of cryptosporidiosis in humans and animals. *Microbes Infect* 2004; 6: 773–85. DOI: 10.1016/j.mic-

inf.2004.02.021

41. Ng J, Pavlasek I, Ryan U. Identification of novel *Cryptosporidium* genotypes from avian hosts. *Appl Environ Microbiol* 2006; 72: 7548–53. DOI: 10.1128/AEM.01352-06

42. Santana BN, Kurahara B, Nakamura AA, et al. Detection and characterization of *Cryptosporidium* species and genotypes in three chicken production systems in Brazil using different molecular diagnosis protocols. *Prev Vet Med* 2018; 151: 73–8. DOI: 10.1016/j.prevetmed.2018.01.007

43. McEvoy JM, Giddings CW. Cryptosporidium in commercially produced turkeys on-farm and postslaughter. *Lett Appl Microbiol* 2009; 48: 302–6. DOI: 10.1111/j.1472-765X.2008.02516.x

44. Levine ND. Protozoan parasites of domestic animals and of man. Minneapolis: Burgess Publishing, 1961: 412.

45. Proctor SJ, Kemp RL. *Cryptosporidium anserinum* sp. n. (Sporozoa) in a domestic goose *Anser anser* L, from Iowa. *J Protozool* 1974; 21: 664–6. DOI: 10.1111/j.1550-

46. Blagburn BL, Lindsay DS, Hoerr FJ, Atlas AL, Toivio-Kinnucan M. *Cryptosporidium* sp. infection in the proventriculus of an Australian diamond firetail finch (*Staganoplura bella*: Passeriformes, Estrildidae). *Avian Dis* 1990; 34: 1027–30. DOI: 10.2307/1591401

47. Pavlasek I. Cryptosporidia: biology diagnosis, host spectrum specificity and the environment. *Klin Mikrobiol Infekc Lek* 1999; 3: 290–301.

48. Pavlasek I. Findings of cryptosporidia in the stomach of chickens and of exotic and wild birds. *Veterinarstvi* 2001; 51: 103–8.

49. Shaapan RM, Khalil FAM, Abou El Ezz MT. Cryptosporidiosis and toxoplasmosis in native quails of Egypt. *Res J Vet Sci* 2011; 4: 30–6. DOI: 10.3923/rjvs.2011.30.36

50. Nagwa EA, El-Akabawy LM, El-Madawy RS, Toulan EI. Studies on intestinal protozoa of poultry in Gharbia governorate. *Benha Vet Med J* 2013; 25: 78–83.

51. Kalifa MM, Nassar AM, Nisreen EM, Abdel-Wahab AM. Cryptosporidium species in ducks: parasitological, serological and molecular studies in Egypt. *Int J Adv Res Biol Sci* 2016; 3: 23–31.

52. Abe N, Makino I. Multilocus genotypic analysis of *Cryptosporidium* isolates from cockatiels, Japan. *Parasitol Res* 2010; 106: 1491–7. DOI: 10.1007/s00436-010-

53. Jellison KL, Distel DL, Hemond HF, Schauer DB. Phylogenetic analysis of the hypervariable



- region of the 18S rRNA gene of *Cryptosporidium* oocysts in feces of Canada geese (*Branta canadensis*): evidence for five novel genotypes. *Appl Environ Microbiol* 2004; 70: 452–8. DOI: 10.1128/AEM.70.1.452-458.2004
54. Zhou L, Kassa H, Tischler ML, Xiao L. Host-adapted *Cryptosporidium* spp. in Canada geese (*Branta canadensis*). *Appl Environ Microbiol* 2004; 70: 4211–5. DOI: 10.1128/AEM.70.7.4211-4215.2004
55. Nakamura AA, Simoes DC, Antunes RG, da Silva DC, Meireles MV. Molecular characterization of *Cryptosporidium* spp. from fecal samples of birds kept in captivity in Brazil *Vet Parasitol* 2009; 166: 47–51. DOI: 10.1016/j.vetpar.2009.07.033
56. Meireles MV, Soares RM, Santos MM, Genari SM. Biological studies and molecular characterization of a *Cryptosporidium* isolate from ostriches (*Struthio camelus*). *J Parasitol* 2006; 92: 623–6. DOI: 10.1645/0022-395(2006)92[623:BSAMCO]2.0.CO;2.
57. Nguyen ST, Fukuda Y, Tada C, et al. Prevalence and molecular characterization of *Cryptosporidium* in ostriches (*Struthio camelus*) on a farm in central Vietnam. *Exp Parasitol* 2013; 133: 8–11. DOI: 10.1016/j.exppara.2012.10.010
58. Makino I, Abe N, Reavill DR. *Cryptosporidium* avian genotype III as a possible causative agent of chronic vomiting in peach-faced lovebirds (*Agapornis roseicollis*). *Avian Dis* 2010; 54: 1102–7. DOI: 10.1637/9227-123009-case.1
59. Qi M, Wang R, Ning C, et al. *Cryptosporidium* spp. in pet birds: genetic diversity and potential public health significance. *Exp Parasitol* 2011; 128: 336–40. DOI: 10.1016/j.exppara.2011.04.003
60. Sevá AP, Funada MR, Richtzenhain L, et al. Genotyping of *Cryptosporidium* spp. from free-living wild birds from Brazil. *Vet Parasitol* 2011; 175: 27–32. DOI: 10.1016/j.vetpar.2010.09.031
61. Gomes RS, Huber F, da Silva S, do Bomfim TC. *Cryptosporidium* spp. parasitize exotic birds that are commercialized in markets, commercial aviaries, and pet shops. *Parasitol Res* 2012; 110: 1363–70. DOI: 10.1007/s00436-011-2636-5
62. Nakamura AA, Homem CG, Silva AMJ, Meireles MV. Diagnosis of gastric cryptosporidiosis in birds using a duplex real-time PCR assay. *Vet Parasitol* 2014; 205: 7–13. DOI: 10.1016/j.vetpar.2014.07.033
63. Kik MJL, van Asten AJAM, Lenstra JA, Kirpensteijn J. Cloaca prolapse and cystitis in green iguana (*Iguana iguana*) caused by a novel *Cryptosporidium* species. *Vet Parasitol* 2011; 175: 165–7. DOI: 10.1016/j.vetpar.2010.10.002
64. Xiao L, Fayer R, Ryan U, Upton SJ. *Cryptosporidium* taxonomy: recent advances and implications for public health. *Clin Microbiol Rev* 2004; 17: 72–97. DOI: 10.1128/cmr.17.1.72-97.2004
65. Tarwid JN, Cawthorn RJ, Riddell C. *Cryptosporidiosis* in the respiratory tract of turkeys in Saskatchewan. *Avian Dis* 1985; 29(2): 528–32. DOI: 10.2307/1590516
66. Lindsay DS, Blagburn BL, Sundermann CA. Host specificity of *Cryptosporidium* sp. isolated from chickens. *J Parasitol* 1986; 72(4): 565–8. DOI: 10.2307/3281511
67. Sreter T, Varga I. *Cryptosporidiosis* in birds: a review. *Vet Parasitol* 2000; 87(4): 261–79. DOI: 10.1016/S0304-4017(99)00178-8
68. Richter D, Wiegand-Tripp G, Burkhardt E, Kaleta EF. Natural infections by *Cryptosporidium* sp. in farm-raised ducks and geese. *Avian Pathol* 1994; 23(2): 277–86. DOI: 10.1080/03079459408418995
69. Lindsay DS, Blagburn BL, Sundermann CA, Hoerr FJ. Experimental infections in domestic ducks with *Cryptosporidium baileyi* isolated from chickens. *Avian Dis* 1989; 33: 69–73. DOI: 10.2307/1591069
70. Ozkul IA, Aydin Y. Small-intestinal cryptosporidiosis in a young pigeon. *Avian Pathol* 1994; 23: 369–72. DOI: 10.1080/03079459408419006
71. Rodriguez F, Oros J, Rodriguez JL, et al. Intestinal cryptosporidiosis in pigeons (*Columba livia*). *Avian Dis* 1997; 41: 748–50. DOI: 10.2307/1592171
72. Radfar MH, Asl EN, Seghinsara HR, Dehaghi MM, Fathi S. Biodiversity and prevalence of parasites of domestic pigeons (*Columba livia domestica*) in a selected semiarid zone of South Khorasan, Iran. *Trop Anim Health Prod* 2012; 44: 225–9. DOI: 10.1007/s11250-011-0002-3
73. Koompapong K, Mori H, Thammasonthijarn N, et al. Molecular identification of *Cryptosporidium* spp. in seagulls, pigeons, dogs, and cats in Thailand. *Parasite* 2014; 21: 52. DOI: 10.1051/parasite/2014053
74. Li J, Lin X, Zhang L, et al. Molecular characterization of *Cryptosporidium* spp. in domestic pigeons (*Columba livia domestica*) in Guangdong province, southern China. *Parasitol Res* 2015; 114: 2237–41. DOI: 10.1007/s00436-015-4415-1
75. Oliveira BCM, Ferrari ED, da Cruz Pane-

- gossi MF, et al. First description of *Cryptosporidium parvum* in carrier pigeons (*Columba livia*). *Vet Parasitol* 2017; 243: 148–50. DOI: 10.1016/j.vetpar.2017.06.023\
76. Tham VL, Kniesberg S, Dixon BR. Cryptosporidiosis in quails. *Avian Pathol* 1982; 11: 619–26. DOI: 10.1080/03079458208436138
77. Murakami S, Miyama M, Ogawa A, Shimada J, Nakane T. Occurrence of conjunctivitis, sinusitis and upper region tracheitis in Japanese quail (*Coturnix coturnix japonica*), possibly caused by *Mycoplasma gallisepticum* accompanied by *Cryptosporidium* sp. infection. *Avian Pathol* 2002; 31: 363–70. DOI: 10.1080/030794502201633
78. Wang R, Wang F, Zhao J, et al. *Cryptosporidium* spp. in quails (*Coturnix coturnix japonica*) in Henan, China: molecular characterization and public health significance. *Vet Parasitol* 2012; 187: 534–7. DOI: 10.1080/03079457.2010.518314
79. Cardozo SV, Teixeira Filho WL, Lopes CW. Experimental transmission of *Cryptosporidium baileyi* (Apicomplexa: Cryptosporidiidae) isolated of broiler chicken to Japanese quail (*Coturnix japonica*). *Rev Bras Parasitol Vet* 2005; 14: 119–24.
80. Allwright DM, Wessels J. *Cryptosporidium* species in ostriches. *Vet Rec* 1993; 133: 24. DOI: 10.1136/vr.133.1.24-a
81. Gajadhar AA. *Cryptosporidium* species in imported ostriches and consideration of possible implications for birds in Canada. *Can Vet J* 1993; 34: 115–6.
82. Gajadhar AA. Host specificity studies and oocyst description of a *Cryptosporidium* sp. isolated from ostriches. *Parasitol Res* 1994; 80: 316–9. DOI: 10.1007/BF02351873
83. Penrith ML, Burger WP. A *Cryptosporidium* sp in an ostrich. *J S Afr Vet Assoc* 1993; 64: 60–1.
84. Penrith ML, Bezuidenhout AJ, Burger WP, Putterill JF. Evidence for cryptosporidial infection as a cause of prolapse of the phallus and cloaca in ostrich chicks (*Struthio camelus*). *Onderstepoort J Vet Res* 1994; 6: 283–9.
85. Ponce Gordo F, Herrera S, Castro AT, García Duran B, Martínez Días RA. Parasites from farmed ostriches (*Struthio camelus*) and rheas (*Rhea americana*) in Europe. *Vet Parasitol* 2002; 107: 137–60. DOI: 10.1016/s0304-4017(02)00104-8.
86. Oliveira FCR, Ederli NB, Ederli BB, Albuquerque MC, Santos MD. Occurrence of *Cryptosporidium* spp. oocysts (Apicomplexa, Cryptosporidiidae) in ostriches, *Struthio camelus* L., 1758 (Aves, Struthionidae) reared in North and Lowered Coastline regions of the state of Rio de Janeiro, Brazil. *Rev Bras Parasitol Vet* 2008; 17: 322–5.
87. Sivajothi S, Sudhakara Reddy B. Cryptosporidiosis in pet birds-zoonotic alert to kids. *Int J Avian Wildlife Biol* 2018; 3: 45–6. DOI: 10.15406/ijawb.2018.03.00051
88. van Zeeland YR, Schoemaker NJ, Kik MJ, van der Giessend JW. Upper respiratory tract infection caused by *Cryptosporidium baileyi* in three mixed-bred falcons (*Falco rusticolus* x *Falco cherrug*). *Avian Dis* 2008; 52: 357–63. DOI: 10.1637/8121-100207-Case.1
89. Molina-Lopez RA, Ramis A, Martin-Vazquez S, et al. *Cryptosporidium baileyi* infection associated with an outbreak of ocular and respiratory disease in otus owls (*Otus scops*) in a rehabilitation centre. *Avian Pathol* 2010; 39: 171–6. DOI: 10.1080/03079451003717589
90. Chelladurai JJ, Clark ME, Kvàè M, et al. *Cryptosporidium galli* and novel *Cryptosporidium* avian genotype VI in North American red-winged black birds (*Agelaius phoeniceus*). *Parasitol Res* 2016; 115: 1901–6. DOI: 10.1007/s00436-016-4930-8
91. Silverlas C, Mattsson JG, Insulander M, Lebbad M. Zoonotic transmission of *Cryptosporidium meleagridis* on an organic Swedish farm. *Int J Parasitol* 2012; 42: 963–7. DOI: 10.1016/j.ijpara.2012.08.008
92. Samad MA. Public health threat caused by zoonotic diseases in Bangladesh, *Bangl J Vet Med* 2011; 9: 95–120. DOI: 10.3329/bjvm.v9i2.13451
93. Majewska AC, Graczyk TK, Slodkiewicz-Kowalska A, et al. The role of free-ranging, captive, and domestic birds of western Poland in environmental contamination with *Cryptosporidium parvum* oocysts and *Giardia lamblia* cysts. *Parasitol Res* 2009; 104: 1093–9. DOI: 10.1007/s00436-008-1293-9
94. Quah JX, Ambu S, Lim YA, Mahdy MA, Mak JW. Molecular identification of *Cryptosporidium parvum* from avian hosts. *Parasitology* 2011; 138: 533–7. DOI: 10.1017/s0031182010001691
95. Goodwin MA, Steffens WL, Russell ID, Brown J. Diarrhea associated with intestinal cryptosporidiosis in turkeys. *Avian Dis* 1988; 32: 63–7. DOI: 10.2307/1590949
96. Gharagozlou MJ, Dezfoulan O, Rahbari S, et al. Intestinal cryptosporidiosis in turkeys in Iran. *J Vet Med A Physiol Pathol Clin Med* 2006; 53:

- 282–5. DOI: 10.1111/j.1439-0442.2006.00843.x
97. Bermudez AJ, Ley DH, Levy MG, et al. Intestinal and bursal cryptosporidiosis in turkeys following inoculation with *Cryptosporidium* sp. isolated from commercial poult. *Avian Dis* 1988; 32: 445–50. DOI: 10.2307/1590910
98. Woodmansee DB, Pavlásek I, Pohlenz JFL, Moon HW. Subclinical cryptosporidiosis of turkeys in Iowa. *J Parasitol* 1988; 74: 898–900. DOI: 10.2307/3282279
99. Fayer R, Speer CA, Dubey JP. The general biology of *Cryptosporidium*. In: Fayer R, Xiao L, eds. *Cryptosporidium* and cryptosporidiosis. New York : CRC Press, 1997.
100. Glisson JR, Brown TP, Brugh M, Page RK, Kleven SH, Davis RB. Sinusitis in turkeys associated with respiratory cryptosporidiosis. *Avian Dis* 1984; 28(3): 783–90.
101. Mason RW. Conjunctival cryptosporidiosis in a duck. *Avian Dis* 1986; 30: 598–600.
102. O'Donoghue PJ, Tham VL, de Saram WG, Paull KL, McDermott S. Cryptosporidium infections in birds and mammals and attempted cross-transmission studies. *Vet Parasitol* 1987; 26: 1–11. DOI: 10.1016/0304-4017(87)90071-9
103. Randall CJ. Conjunctivitis in pheasants associated with cryptosporidial infection. *Vet Rec* 1986; 118: 211. DOI: 10.1136/vr.118.8.211
104. Mason RW, Hartley WJ. Respiratory cryptosporidiosis in a peacock chick. *Avian Dis* 24(3): 1980; 771–6.
105. Coldwell L, Caldow G, Holliman A, et al. *Cryptosporidium baileyi* in wild red grouse with 'bulgy eye'. *Vet Rec* 2012; 170: 603–4. DOI: 10.1136/vr.e3940
106. Ley DH, Moresco A, Frasca S Jr. Conjunctivitis, rhinitis, and sinusitis in cliff swallows (*Petrochelidon pyrrhonota*) found in association with *Mycoplasma sturni* infection and cryptosporidiosis. *Avian Pathol* 2012; 41: 395–401. DOI: 10.1080/03079457.2012.697624
107. Bougiouklis PA, Weissenböck H, Wells A, et al. Otitis media associated with *Cryptosporidium baileyi* in a Saker falcon (*Falco cherrug*). *J Comp Pathol* 2013; 148: 419–23. DOI: 10.1016/j.jcpa.2012.09.005
108. Baines D, Newborn D, Richardson M. Spread of *Cryptosporidium baileyi* in red grouse *Lagopus lagopus scoticus*. *Vet Rec* 2014; 175: 149. DOI: 10.1136/vr.102275
109. Goodwin MA. Cryptosporidiosis in birds: a review. *Avian Pathol* 1989; 18: 365–84. DOI: 10.1080/03079458908418612
110. Blagburn BL, Lindsay DS, Giambone JJ, Sundermann CA, Hoerr FJ. Experimental cryptosporidiosis in broiler chickens. *Poultry Sci* 1987; 66: 442–9. DOI: 10.3382/ps.0660442
111. Meireles MV, Paulillo AC, Silva GS, et al. Experimental infection with *Cryptosporidium baileyi* in broilers raised on floor-pens. *Braz J Poult Sci* 1999; 1: 37–42.
112. Abbassi H, Coudert F, Dambrine G, Chérel Y, Naciri M. Effect of *Cryptosporidium baileyi* in specific pathogen free chickens vaccinated (CVI988/ Rispens) and challenged with HPRS-16 strain of Marek's. *Avian Pathol* 2000; 29: 623–34. DOI: 10.1080/03079450020016887
113. Hornok S, Heijmans JF, Békési L, et al. Interaction of chicken anaemia virus and *Cryptosporidium baileyi* in experimentally infected chickens. *Vet Parasitol* 1998; 76: 43–55. DOI: 10.1016/s0304-4017(97)00046-0
114. Levy MG, Ley DH, Barnes HJ, Gerig TM, Corbett WT. Experimental cryptosporidiosis and infectious bursal disease virus infection of specific pathogen-free chickens. *Avian Dis* 1988; 32: 803–11. DOI: 10.2307/1591002
115. Guy JS, Levy MG, Ley DH, Barnes HJ, Gerig TM. Interaction of reovirus and *Cryptosporidium baileyi* in experimentally infected chickens. *Avian Dis* 1988; 32: 381–90. DOI: 10.2307/1590901
116. Scott TR. Our current understanding of humoral immunity of poultry. *Poult Sci* 2004; 83: 574–9. DOI: <https://doi.org/10.1093/ps/83.4.574>
117. Naciri M, Mazzella O, Coudert F. Interactions cryptosporidies-virus sauvage ou vaccinal de la maladie de Marek chez le poulet. *Rec Méd Vét* 1989; 165: 383–7.
118. Rhee JK, Kim HC, Lee SB, Yook SY. Immunosuppressive effect of *Cryptosporidium baileyi* infection on vaccination against Newcastle disease in chicks. *Korean J Parasitol* 1998a; 36: 121–5. DOI: 10.3347/kjp.1998.36.2.121
119. Eladl AH, Hamed HR, Khalil MR. Consequence of Cryptosporidiosis on the immune response of vaccinated broiler chickens against Newcastle disease and/or avian influenza. *Vet Res Commun* 2014; 38: 237–47. DOI: 10.1007/s11259-014-9610-5
120. Rhee JK, Yang HJ, Yook SY, Kim HC. Immunosuppressive effect of *Cryptosporidium baileyi* infection on vaccination against avian infectious bronchitis in chicks. *Korean J Parasitol* 1998b;



36: 203–6. DOI: 10.3347/kjp.1998.36.3.203

121. Hao YX, Yang JM, He C, Liu Q, McAllister TA. Reduced serologic response to avian influenza vaccine in specific-pathogen-free chicks inoculated with *Cryptosporidium baileyi*. Avian Dis 2008; 52: 690–3. DOI: 10.1637/8370-052608-reg.1

122. Goodwin MA, Brown J. Intestinal cryptosporidiosis in chickens. Avian Dis 1989; 33: 770–7. DOI: 10.2307/1591159

123. Meireles MV, Paulillo AC, Silva GS, et al. Influência da infecção experimental com *Cryptosporidium baileyi* na resposta imune de frangos de corte vacinados contra a doença de Newcastle. Rev Bras Cienc Vet 1998; 5: 15–9. DOI: 10.4322/rbcv.2015.092

124. Ranck FM Jr, Hoerr FJ. Cryptosporidia in the respiratory tract of turkeys. Avian Dis 1987; 31: 389–91. DOI: 10.2307/1590893

125. Ryan UM, Xiao L. Birds. In: Fayer R, Xiao L, eds. Cryptosporidium and cryptosporidiosis. Boca Raton : CRC Press, 2008.

126. Guy JS, Levy MG, Ley DH, Barnes HJ. Experimental reproduction of enteritis in bobwhite quail (*Colinus virginianus*) with *Cryptosporidium* and reovirus. Avian Dis 1987; 31: 713–22. DOI: 10.2307/1591021

127. Jardine JE, Verwoerd DJ. Pancreatic cryptosporidiosis in ostriches. Avian Pathol 1997; 26: 665–70. DOI: 10.1080/03079459708419243

128. Goodwin MA, Krabill VA. Diarrhea associated with small-intestinal cryptosporidiosis in a budgerigar and in a cockatiel. Avian Dis 1989; 33: 829–33. DOI: 10.2307/1591170

129. Lindsay DS, Blagburn BL, Hoerr FJ. Small intestinal cryptosporidiosis in cockatiels associated with *Cryptosporidium baileyi*-like oocysts. Avian Dis 1990; 34: 791–3. DOI: 10.2307/1591283

130. Morgan UM, Xiao L, Limor J, et al. *Cryptosporidium meleagridis* in an Indian ring-necked parrot (*Psittacula krameri*). Aust Vet J 2000; 78: 182–3. DOI: 10.1111/j.1751-0813.2000.tb10589.x

131. Belton DJ, Powell IB. Cryptosporidiosis in lovebirds (*Agapornis* sp.). N Z Vet J 1987; 35: 15. DOI: 10.1080/00480169.1987.35364

132. Zylan K, Bailey T, Smith HV, et al. An outbreak of cryptosporidiosis in a collection of Stone curlews (*Burhinus oediacnemus*) in Dubai. Avian Pathol 2008; 37: 521–6. DOI: 10.1080/03079450802357019

133. Clubb S. What is your diagnosis? J Avian Med Surg 1997; 11: 41–2.

134. Antunes RG, Simões DC, Nakamura AA, Meireles MV. Natural infection with *Cryptosporidium galli* in canaries (*Serinus canaria*), in a cockatiel (*Nymphicus hollandicus*), and in lesser seed-finches (*Oryzoborus angolensis*) from Brazil. Avian Dis 2008; 52: 702–5. DOI: 10.1637/8356-051208-case.1

135. Silva DC, Homem CG, Nakamura AA, et al. Physical, epidemiological, and molecular evaluation of infection by *Cryptosporidium galli* in Passeriformes. Parasitol Res 2010; 107: 271–7. DOI: 10.1007/s00436-010-1858-2.

136. Ravich ML, Reavill DR, Hess L, Childress AL, Wellehan JFX Jr. Gastrointestinal cryptosporidiosis in captive psittacine birds in the United States: a case review. J Avian Med Surg 2014; 28: 297–303. DOI: 10.1647/1082-6742-28.4.297

137. Qi M, Huang L, Wang R, et al. Natural infection of *Cryptosporidium muris* in ostriches (*Struthio camelus*). Vet Parasitol 2014; 205: 518–22. DOI: 10.1016/j.vetpar.2014.06.035

138. Ryan U, Xiao L, Read C, et al. Identification of novel *Cryptosporidium* genotypes from the Czech Republic. Appl Environ Microbiol 2003b; 69: 4302–7. DOI: 10.1128/AEM.69.7.4302-4307.2003.

139. Dhillon AS, Thacker HL, Dietzel AV, Winterfield RW. Respiratory cryptosporidiosis in broiler chickens. Avian Dis 1981; 25: 747–51.

140. Sponseller JK, Griffiths JK, Tzipori S. The evolution of respiratory cryptosporidiosis: evidence for transmission by inhalation. Clin Microbiol Rev 2014; 27: 575–86. DOI: 10.1128/CMR.00115-13.

141. Fayer R, Morgan U, Upton SJ. Epidemiology of *Cryptosporidium*: transmission, detection and identification. Int J Parasitol 2000; 30: 1305–22. DOI: 10.1016/S0020-7519(00)00135-1.

142. Papadopoulou C, Xylouri E, Zisides N. Cryptosporidial infection in broiler chickens in Greece. Avian Dis 1988; 32: 842–3. DOI: 10.2307/1591010

143. Kichou F, Saghir F, El Hamidi M. Natural *Cryptosporidium* sp. infection in broiler chickens in Morocco. Avian Pathol 1996; 25: 103–11. DOI: 10.1080/03079459608419124

144. Soltane R, Guyot K, Dei-Cas E, Ayadi A. Prevalence of *Cryptosporidium* spp. (Eucoccidiorida: Cryptosporiidae) in seven species of farm an-



- imals in Tunisia. *Parasite* 2007; 14: 335–8. DOI: 10.1051/parasite/2007144335
145. Sevinc F, Irmak K, Sevinc M. The prevalence of *Cryptosporidium parvum* infection in the diarrhoeic and non-diarrhoeic calves. *Revue Méd Vét* 2003; 154: 357–61.
146. Gabr NS, Abdellatif MZM, ElHafeez EHA, Rabou RAM. Comparison between Elisa and various stains techniques in laboratory diagnosis of cryptosporidiosis. *J Egypt Soc Parasitol* 2014; 44: 509–16. DOI: 10.12816/jesp.2014.90410
147. Itakura C, Goryo M, Umemura T. Cryptosporidial infection in chickens. *Avian Pathol* 1984; 13: 487–99. DOI: 10.1080/03079458408418550
148. Shemshadi B, Bahadori SR, Mozafari A. Study on cryptosporidiosis incidence in broilers in Garmsar region, Iran. *Comp Clin Pathol* 2011; 20: 143–9. DOI: 10.1007/s00580-010-0970-0
149. Sonzogni-Desautels K, Di Lenardo TZ, Renteria AE, et al. A protocol to count *Cryptosporidium* oocysts by flow cytometry without antibody staining. *PLoS Negl Trop Dis* 2019; 13(3): e0007259. DOI: 10.1371/journal.pntd.0007259.
150. Farrington M, Winters S, Walker C, Miller R, Rubenstein D. *Cryptosporidium* antigen detection in human feces by reverse passive hemagglutination assay. *J Clin Microbiol* 1994; 32: 2755–9. DOI: 10.1128/jcm.32.11.2755-2759.1994
151. Ndao M. Diagnosis of parasitic diseases: old and new approaches. *Interdiscip Perspect Infect Dis* 2009; 2009: e278246. DOI: 10.1155/2009/278246
152. Fereig RM, Abdelbaky HH, Ihara F, Nishikawa Y. Development and evaluation of the first immunochromatographic test that can detect specific antibodies against *Cryptosporidium parvum*. *Acta Trop* 2018; 185: 349–56. DOI: 10.1016/j.actatropica.2018.06.019
153. Hassanein SM, Abd-El-Latif MM, Hassanin OM, Abd-El-Latif LM, Ramadan NI. *Cryptosporidium* gastroenteritis in Egyptian children with acute lymphoblastic leukemia: Magnitude of the problem. *Infection* 2012; 40: 279–84. DOI: 10.1007/s15010-011-0230-5
154. Fereig RM, AbouLaila MR, Mohamed SG, et al. Serological detection and epidemiology of *Neospora caninum* and *Cryptosporidium parvum* antibodies in cattle in southern Egypt. *Acta Trop* 2016; 162: 206–11. DOI: 10.1016/j.actatropica.2016.06.032
155. Masatani T, Fereig RM, Otomaru K, et al. Seroprevalence of *Cryptosporidium parvum* and *Neospora caninum* in cattle in the southern Kyushu region of Japan. *Parasitol Int* 2018; 67: 763–7. DOI: 10.1016/j.parint.2018.08.001
156. Amar CF, Dear PH, McLauchlin J. Detection and identification by real time PCR-RFLP analyses of *Cryptosporidium* species from human feces. *Lett Appl Microbiol* 2004; 38: 217–22. DOI: 10.1111/j.1472-765X.2004.01473.x
157. Xiao L, Escalante L, Yang C. Phylogenetic analysis of *Cryptosporidium* parasites based on the small-subunit rRNA gene locus. *Appl Environ Microbiol* 1999; 65: 1578–83. DOI: 10.1128/aem.65.4.1578-1583.1999
158. Mahfouz ME, Mira N, Amer S. Prevalence and genotyping of *Cryptosporidium* spp. in farm animals in Egypt. *J Vet Med Sci* 2014; 76: 1569–75. DOI: 10.1292/jvms.14-0272
159. Spano F, Putignani L, McLauchlin J. PCR-RFLP analysis of the *Cryptosporidium* oocyst wall protein (COWP) gene discriminates between *C. wrairi* and *C. parvum*, and between *C. parvum* isolates of human and animal origin. *FEMS Microbiol Lett* 1997; 150: 209–17. DOI: 10.1016/s0378-1097(97)00115-8
160. Jex AR, Gasser RB. Genetic richness and diversity in *C. hominis* and *C. parvum* reveals major knowledge gaps and a need for the application of Next generation technologies research review. *Biotechnol Adv* 2010; 28: 17–26. DOI: 10.1016/j.biotechadv.2009.08.003
161. de Graaf DC, Vanopdenbosch E, Ortega-Mora LM, Abbassi H, Peeters JE. A review of the importance of cryptosporidiosis in farm animals. *Int J Parasitol* 1999; 29: 1269–87. DOI: 10.1016/s0020-7519(99)00076-4
162. Amer S, Honma H, Ikarashi M, et al. *Cryptosporidium* genotypes and subtypes in dairy calves in Egypt. *Vet Parasitol* 2010; 169: 382–6. DOI: 10.1016/j.vetpar.2010.01.017
163. Ibrahim MA, Abdel-Ghany AE, Abdel-Latef GK, Abdel-Aziz SA, Aboelhadid SM. Epidemiology and public health significance of *Cryptosporidium* isolated from cattle, buffaloes, and humans in Egypt. *Parasitol Res* 2016; 115: 2439–48. DOI: 10.1007/s00436-016-4996-3
164. Alagappan A, Bergquist PL, Ferrari BC. Development of a two-color fluorescence in situ hybridization technique for species-level identification of human-infectious *Cryptosporidium* spp. *Appl Environ Microbiol* 2009; 75: 5996–8. DOI: 10.1128/AEM.00643-09
165. Wong YP, Othman S, Lau YL, Radu S, Chee HY. Loop-mediated isothermal amplification (LAMP): a versatile technique for detection of mi-

- cro-organisms. *J Appl Microbiol* 2018; 124: 626–43. DOI: 10.1111/jam.13647
166. Fayer R, Ungar BLP. *Cryptosporidium* spp. and cryptosporidiosis. *Microbiol Rev* 1986; 50: 458–83.
167. Abou-Eisha AM. Cryptosporidial infection in man and farm animals in Ismailia governorate. *Vet Med J Giza* 1994; 42: 107–11.
168. Abou-Eisha AM, Hussein MM, Abdel-Aal AA, Saleh RE. Cryptosporidium in drinking water sources and its zoonotic importance. *Minufiya Vet J* 2000; 1: 101–6.
169. Xiao L, Ryan U. Cryptosporidium. In: Xiao L, Ryan U, eds. *Biology of foodborne parasites*. Boca Raton : CRC Press, 2015: 77–95.
170. Preiser G, Preiser L, Madeo L. An outbreak of cryptosporidiosis among veterinary science students who work with calves. *J Am Coll Health* 2003; 51: 213–5. DOI: 10.1080/07448480309596353
171. Gait R, Soutar RH, Hanson M, Fraser C, Chalmers R. Outbreak of cryptosporidiosis among veterinary students. *Vet Rec* 2008; 162: 843–5. DOI: 10.1136/vr.162.26.843
172. Graczyk TK, Fayer R, Cranfield MR. Zoonotic transmission of *Cryptosporidium parvum*: implications for waterborne cryptosporidiosis. *Parasitol Today* 1998; 13: 348–51. DOI: 10.1016/S0169-4758(97)01076-4
173. Graczyk TK, Majewska AC, Schwab KJ. The role of birds in dissemination of human waterborne enteropathogens. *Trends Parasitol* 2008; 24: 55–9. DOI: 10.1016/j.pt.2007.10.007
174. Plutzer J, Tomor B. The role of aquatic birds in the environmental dissemination of human pathogenic *Giardia duodenalis* cysts and *Cryptosporidium* oocysts in Hungary. *Parasitol Int* 2009; 58: 227–31. DOI: 10.1016/j.parint.2009.05.004
175. Wong SSY. The sick returned traveller. *Top Updat Hong Kong Coll Pathol* 2016; 11: 1–10.
176. Chen XM, Keitely JS, Paya CV, Larusso NF. Cryptosporidiosis. *N Engl J Med* 2002; 346: 1723–31. DOI: 10.1056/nejmra013170
177. Thomson S, Hamilton CA, Hope JC, et al. Bovine cryptosporidiosis: impact, host-parasite interaction and control strategies. *Vet Res* 2017; 48: 42. DOI: 10.1186/s13567-017-0447-0
178. Morgan-Ryan UM, Fall A, Ward LA, et al. *Cryptosporidium hominis* n. sp. (Apicomplexa: Cryptosporidiidae) from *Homo sapiens*. *J Eukaryot Microbiol* 2002; 49: 433–40. DOI: 10.1111/j.1550-7408.2002.tb00224.x
179. Chappell CL, Okhuysen PC, Langer-Curry RC, et al. *Cryptosporidium meleagridis* infectivity in healthy adult volunteers, *Am J Trop Med Hyg* 2011; 85: 238–42. DOI: 10.4269/ajtmh.2011.10-0664
180. Xiao L. Molecular epidemiology of cryptosporidiosis: an update. *Exp Parasitol* 2010; 124: 80–9. DOI: 10.1016/j.exppara.2009.03.018
181. Xiao L, Feng Y. Zoonotic cryptosporidiosis. *FEMS Immunol Med Microbiol* 2008; 52: 309–23. DOI: 10.1111/j.1574-695x.2008.00377.x
182. Chalmers RM, Giles M. Zoonotic cryptosporidiosis in the UK: challenges for control. *J Appl Microbiol* 2010; 109: 1487–97. DOI: 10.1111/j.1365-2672.2010.04764.x
183. Elwin K, Hadfield SJ, Robinson G, Chalmers RM. The epidemiology of sporadic human infections with unusual cryptosporidia detected during routine typing in England and Wales, 2000–2008. *Epidemiol Infect* 2012; 140: 673–83. DOI: 10.1017/S0950268811000860
184. Insulander M, Silverlas C, Lebbad M, et al. Molecular epidemiology and clinical manifestations of human cryptosporidiosis in Sweden. *Epidemiol Infect* 2013; 141: 1009–20. DOI: 10.1017/S0950268812001665
185. Steiner KL, Ahmed S, Gilchrist CA, et al. Species of cryptosporidia causing subclinical infection associated with growth faltering in rural and urban Bangladesh: a birth cohort study. *Clin Infect Dis* 2018; 67: 1347–55. DOI: 10.1093/cid/ciy310
186. Stensvold CR, Beser J, Axén C, Lebbad M. High applicability of a novel method for gp60-based subtyping of *Cryptosporidium meleagridis*. *J Clin Microbiol* 2014; 52: 2311–9. DOI: 10.1128/JCM.00598-14
187. Korpe PS, Gilchrist C, Burkey C, et al. Case-control study of *Cryptosporidium* transmission in Bangladeshi households. *Clin Infect Dis* 2019; 68: 1073–9. DOI: 10.1093/cid/ciy593
188. Messenger AM, Barnes AN, Gray GC. Reverse zoonotic disease transmission (zooanthroponosis): a systematic review of seldom-documented human biological threats to animals. *PLoS One* 2014; 9: e89055. DOI: 10.1371/journal.pone.0089055
189. Aldeyarbi HM, El-Ezz NM, Karanis P. *Cryptosporidium* and cryptosporidiosis: the African perspective. *Environ Sci Pollut Res* 2016; 23: 13811–21. DOI: 10.1007/s11356-016-6746-6
190. Kotloff KL, Nataro JP, Blackwelder WC,

- et al. Burden and aetiology of diarrhoeal disease in infants and young children in developing countries (The Global Enteric Multicenter Study, GEMS): a prospective, case-control study. *Lancet* 2013; 382: 209–22. DOI: 10.1016/s0140-6736(13)60844-2
191. Gabr NS, Ahmad AK, Belal US, Abdel-Hafeez EH, Abd Rabou RAM. Prevalence of *Cryptosporidium* species in human faecal specimens in Minia Governorate, Egypt. *Malaysian J Med Res* 2018; 29: 225–9.
192. Abdel-Hafeez EH, Ahmad AK, Ali BA, Mostafa FA. Opportunistic parasites among immunosuppressed children in Minia District, Egypt. *Korean J Parasitol* 2012; 50: 57–62. DOI: 10.3347/kjp.2012.50.1.57
193. Helmy YA, Krucken J, Nockler K, von Samson-Himmelstjerna G, Zessin KH. Molecular epidemiology of *Cryptosporidium* in livestock animals and humans in the Ismailia province of Egypt. *Vet Parasitol* 2013; 193: 15–24. DOI: 10.1016/j.vetpar.2012.12.015
194. Naser ME, Younis MS, Bayoumi IR, et al. Evaluation of nanogold-beads-based enzyme-linked immunosorbent assay for detection of *Cryptosporidium* antigen in stool samples of diarrheic patients. *Benha Med J* 2017; 34: 88–92. DOI: 10.4103/bmfj.bmfj\_109\_17
195. Mousa KM, Abdel-Tawab AH, Khalil HH, El-Hussieny NA. Diarrhea due to parasites particularly *Cryptosporidium parvum* in great Cairo, Egypt. *J Egypt Soc Parasitol* 2010; 40: 439–50.
196. Abdel-Maboud AI, Rossignol JF, El-Kady MS, Mostafa MS, Kabil SM. Cryptosporidiosis in Benha, study of some recent modalities in diagnosis and treatment. *J Egypt Soc Parasitol* 2000; 30: 717–25.
197. Ali MS, Mahmoud LA, Abaza BE, Ramadan MA. Intestinal spore-forming protozoa among patients suffering from chronic renal failure. *J Egypt Soc Parasitol* 30: 93–100.
198. Shoukry NM, Dawoud HA, Haridy FM. Studies on zoonotic cryptosporidiosis parvum in Ismailia Governorate, Egypt. *J Egypt Soc Parasitol* 2009; 39: 479–88.
199. Hassan SI, Sabry H, Amer NM, et al. Incidence of cryptosporidiosis in immunodeficient cancer patients in Egypt. *J Egyptian Soc Parasitol* 2002; 32: 33–46.
200. Antonios SN, Tolba OA, Othman AA, Saad MA. A preliminary study on the prevalence of parasitic infections in immunocompromised children. *J Egypt Soc Parasitol* 2010; 40: 617–30.
201. El-Badry AA, Al-Antably ASA, Hassan MA, Hanafy NA, AbuSarea EY. Molecular seasonal, age and gender distributions of *Cryptosporidium* in diarrhoeic Egyptians: distinct endemicity. *Eur J Clin Microbiol* 2015; 34(12): 2447–53. DOI: 10.1007/s10096-015-2502-y
202. Chako CZ, Tyler JW, Schultz LG, Chiguma L, Beerntsen BT. Cryptosporidiosis in people: it's not just about the cows. *J Vet Intern Med* 2010; 24: 37–43. DOI: 10.1111/j.1939-1676.2009.0431.x
203. Joachim A. Human cryptosporidiosis: an update with special emphasis on the situation in Europe. *J Vet Med B Infect Dis Vet Public Health* 2004; 51: 251–9. DOI: 10.1111/j.1439-0450.2004.00765.x
204. Barbee SL, Weber DJ, Sobsey MD, Rutala WA. Inactivation of *Cryptosporidium parvum* oocyst infectivity by disinfection and sterilization processes. *Gastrointest Endosc* 1999; 49: 605–11. DOI: 10.1016/s0016-5107(99)70389-5
205. Semenza JC, Nichols G. Cryptosporidiosis surveillance and water-borne outbreaks in Europe. *Eur Commun Dis Bull* 2007; 12: 120–3. DOI: 10.2807/esm.12.05.00711-en
206. Guerrant RL. Cryptosporidiosis: an emerging, highly infectious threat. *Emerg Infect Dis* 1997; 3: 51–7. DOI: 10.3201/eid0301.970106
207. King B, Fanok S, Phillips R, Swaffer B, Monis P. Integrated *Cryptosporidium* assay to determine oocyst density, infectivity, and genotype for risk assessment of source and reuse water. *Appl Environ Microbiol* 2015; 81: 3471–81. DOI: 10.1128/AEM.00163-15
208. Lindsay DS, Blagburn BL, Sundermann CA, Ernest JA. Chemoprophylaxis of cryptosporidiosis in chickens, using halofuginone, salinomycin, lasalocid, or monensin. *Am J Vet Res* 1987; 48: 354–5.
209. Shahiduzzaman M, Dausgschies A. Therapy and prevention of cryptosporidiosis in animals. *Vet Parasitol* 2012; 188: 203–14. DOI: 10.1016/j.vetpar.2012.03.052
210. Hassan D, Farghali M, Eldeek H, et al. Antiprotozoal activity of silver nanoparticles against *Cryptosporidium parvum* oocysts: new insights on their feasibility as a water disinfectant. *J Microbiol Meth* 2019; 165: 105698. DOI: 10.1016/j.mimet.2019.105698
211. Aly I, Taher H, El-Feky F. Efficacy of low

and high dose of paromomycin sulfate for treatment of cryptosporidiosis in immunosuppressed infected-mice. *Global Vet* 2015; 15: 137–43.

212. Abdel Megeed KN, Hammam AM, Morsy GH, Khalil FM. Control of cryptosporidiosis in buffalo calves using garlic (*Allium sativum*) and nitazoxanide with special reference to some biochemical parameters. *Global Vet* 2015; 14: 646–55.

213. Carey CM, Lee H, Trevors JT. Biology, persistence and detection of *Cryptosporidium parvum* and *Cryptosporidium hominis* oocyst. *Water Res* 2003; 38: 818–32. DOI: 10.1016/j.watres.2003.10.012

214. Ryan UNA, Fayer R, Xiao L. *Cryptosporidium* species in humans and animals: current understanding and research needs. *Parasitology* 2014; 141: 1667–85. DOI: 10.1017/S0031182014001085

215. Acikgoz Y, Ozkaya O, Bek K, et al. Cryptosporidiosis: a rare and severe infection in a pediatric renal transplant recipient. *Pediatr Transplant* 2012; 16: E115–9. DOI: 10.1111/j.1399-3046.2011.01473.x

216. Wei A, Shibamoto T. Antioxidant/lipoxygenase inhibitory activities and chemical compositions of selected essential oils. *J Agric Food Chem* 2010; 58: 7218–25. DOI: 10.1021/jf101077s

217. Abouel-Nour MF, El-Shewehy DMM, Hamada SF, Morsy TA. The efficacy of three medicinal plants; garlic, ginger and mirazid and a chemical drug metronidazole against *Cryptosporidium parvum*: II- histological changes. *J Egypt Soc Parasitol* 2016; 46: 185–200. DOI: 10.12816/0026164

218. Kim HC, Healey JM. Effects of pine bark extract administered to immunosuppressed adult mice infected with *Cryptosporidium parvum*. *Am*

*J Chin Med* 2001; 29: 469–75. DOI: 10.1142/S0192415X01000484

219. Wahba AA. Studies on efficacy of garlic extract on cryptosporidiosis in experimentally infected mice. *Egypt J Agric Res* 2003; 81: 795–805.

220. Abu El Ezz NMT, Khalil AM, Shaapan RM. Therapeutic effect of onion (*Allium cepa*) cinnamon (*Cinnamomum zeylanicum*) oils on cryptosporidiosis in experimentally infected mice. *Global Vet* 2001; 7: 179–83.

221. Gaafar MR. Efficacy of *Allium sativum* (garlic) against experimental cryptosporidiosis. *Alex J Med* 2011; 48: 59–66.

222. Toulah FH, El-Shafei AA, Al-Rashidi HS. Evaluation of garlic plant and indinavir drug efficacy in the treatment of cryptosporidiosis in experimentally immune-suppressed rats. *J Egypt Soc Parasitol* 2012; 42: 321–8. DOI: 10.12816/0006320

223. Nasir A, Avais M, Khan MS, et al. Treating *Cryptosporidium parvum* infection in calves. *J Parasitol* 2013; 99: 715–7. DOI: 10.1645/12-42.1

224. Zaki WM, El-Amir YO. Therapeutic efficacy of a cysteine proteases inhibitor (phenyl vinyl sulfone) either alone or combined with *Nigella sativa* on experimental cryptosporidiosis. *J Egypt Soc Parasitol* 2018; 48: 165–74. DOI: 10.12816/JESP.2018.77484

225. Sadek HA, Abdel-Rahman SM, Bakir HY, et al. The potential convention of garlic and black seed different extracts as an effective treatment of *Cryptosporidium* spp.: an experimental study. *J Egypt Soc Parasitol* 2020; 50: 613–21. DOI: 10.12816/JESP.2020.131094

226. Fareed G, Scolaro M, Jordan W, Sanders N. The use of a high-dose garlic preparation for the treatment of *Cryptosporidium parvum* diarrhea. *Int Conf AIDS* 1996; 11: 288–97.



## KRIPTOSPORIDIOZA PTIC: POMEMBNA PARAZITSKA BOLEZEN, NEVARNA ZA JAVNO ZDRAVJE

W. A. A. El-Ghany

**Izvelek:** Kriptosporidioza je ena najpomembnejših zoonotskih parazitskih bolezni, ki prizadene številne gostiteljske vrste. Bolezen je razširjena po vsem svetu. Vrste *Cryptosporidium* lahko prizadenejo različne ptičje gostitelje in povzročijo veliko gospodarsko škodo. Resnost simptomov kriptosporidioze pri pticah je različna, od asimptomatične bolezni do hudih črevesnih in/ali dihalnih znakov z visoko smrtnostjo. Diagnoza okužbe s parazitom *Cryptosporidium* temelji predvsem na mikroskopskem odkrivanju oocist, seroloških metodah ali molekularnih tehnikah za identifikacijo različnih vrst povzročitelja. Ljudje in živali so zelo dovzetni za okužbo z različnimi vrstami *Cryptosporidium*, ki so posledica zaužitja kontaminirane hrane ali vode z oocistami ali neposrednega stika z okuženimi gostitelji. Za preprečevanje in nadzor bolezni pri okuženih živalih, pticah in ljudeh ali v njihovi okolici so bile uporabljene različne strategije. Namen tega preglednega članka je bil zato razjasniti vrste povzročiteljev in razširjenost kriptosporidioze ptic, dovzetnost za okužbo in način prenosa ter klinično sliko, laboratorijsko diagnostiko, zoonotski pomen in strategije preprečevanja in nadzora bolezni.

**Ključne besede:** ptičji; *Cryptosporidium*; diagnoza; človeški