

## Strictures of the male urethra: how to perform and evaluate radiourethrography and sonourethrography to avoid mistakes

Darja Babnik Peskar, Alenka Višnar Perovič

*Clinical Institute of Radiology, University Medical Centre, Ljubljana, Slovenia*

---

**Introduction.** Precise evaluation of the urethral stricture localisation, length, depth and quality of wall changes are necessary for the selection of the optimal treatment to prevent recurrences. Decision for urethral dilatation, internal urethrotomy or open surgery depends on urethroscopic, radiourethrographic-RUG, and recently, according to Mc Anninch, also sonourethrographic-SUG results. SUG adds information about the depth and density of spongiofibrosis. Previously published findings of RUG length underestimation, compared to SUG and endoscopy, were responsible for inappropriate treatment and recurrences. In our article, we evaluate SUG as a new imaging method in the diagnosis of urethral strictures and treatment planning, and describe both imaging methods together with usual pitfalls in performance or interpretation, possible reason for incorrect length measurements, and RUG length underestimation.

**Patients and methods.** In the period of 20 months, we evaluated SUG compared to RUG and endoscopy in 51/130 males with suspected urethral strictures.

**Results.** Compared to RUG, sonography was correct in 92 % radiographically detected strictures. Length measurements by sonography were for 22 % shorter than radiographic lengths, which could be explained by radiographic magnification, as it was proved with wire measure placed on penis. Considering radiographic magnification, we did not find important differences in any measurement. Opposite to previously published RUG results compared to endoscopy and SUG, radiographic length underestimation was not found.

**Conclusion.** The combination of both imaging methods provides optimal information about urethral stricture anatomy. We conclude that published radiographic length underestimation could be only a misinterpretation. We realise how important it is to avoid performance mistakes, misinterpretation, wrong comparison and wrong conclusions for proper treatment planning. We advice to perform dynamic RUG according to Mc Callum RW.

*Key words: urethral stricture - radiography - ultrasonography*

---

Received 15 May 2000

Accepted 30 May 2000

Correspondence to: Darja Babnik Peskar, Clinical Radiology Institute, University Medical Centre Ljubljana, Zaloška 7, SI-1525 Ljubljana. Phone: +386 1 143 15 30; Fax: +386 1 133 31 044

## Introduction

### *Etiology, patohistology*

The urethral stricture is the result of inflammation and trauma, and is suspected in the patients with obstructive symptoms, recurrent urinary tract infections, and in cases of inability to pass the catheter. Repeated instrumentation and treatment of recidives, increase a risk for additional iatrogenic trauma with pressure necrosis and secondary inflammation, with penetration into the submucosa and underlying corpus spongiosum, resulting in subepithelial microabscesses, thrombosis and fibrosis- the urethral scar. Inelastic scar shortens the circumference, reduces the urethral lumen, and causes significant urodynamic effect.<sup>1,2</sup>

### *Treatment planning*

In the absence of exposure to infections or additional iatrogenic trauma, the recurrences of strictures after treatment are believed to be the consequence of inappropriate choice of treatment.<sup>1-5</sup>

The localisation and length of stricture are decisional, however the depth and quality of periurethral changes must be included in the treatment planning.<sup>6-10</sup> According to recent literature, urethral dilatation and internal urethrotomy can be curative for short 1 cm long focal strictures, involving the epithelium alone or superficial spongiosum. For diffuse, longer and deeper strictures, reconstructive surgery is advised.<sup>1,11-14</sup> As a first treatment choice, open surgery is indicated in severe urodynamically important strictures with deep spongiofibrosis or full-thickness-scar, for diffuse long stricture, in strictures, which extend into the membranous urethra. In penile region, tension free reanastomoses are limited to 2-3 cm long strictures<sup>10,12,15</sup>, and longer are treated with full-thickness skin or free graft or flap urethroplasty. For strictures

close to the membranous urethra, posterior or transsphincter urethroplasty is necessary.<sup>11</sup>

### *Imaging diagnosis of the urethral strictures*

The location and the length of stricture can be evaluated by urethroscopy or urethrography, and the depth from the appearance of the urethra on contrast studies, the elasticity noted at urethroscopy and the depth and density of the fibrosis evidenced during sonourethrography.<sup>1,2,3,6-11</sup>

### *Aim of the study*

Until recently, radiourethrography was a standard technique in diagnostic imaging of urethral strictures in our department, where we perform 100 radiourethrographies per year. The earlier described sonourethrographic advantages without radiation risks were the reasons for the application of sonourethrography together with radiourethrography to gain information about:

1. Sonourethrography as a new imaging technique in urethral strictures;
2. Radiographic length underestimation compared to sonography - the possible reason for inappropriate treatment decision found in previously published studies, or confirmation of our prediction that the length underestimation could be only interpretational mistake.

## Patients and methods

In the period of 20 months, we performed subsequent radiourethrography (RUG) and sonourethrography (SUG) in 51/130 males (age 21-79 years, mean 52.7) with clinically suspected urethral strictures, according to the urodynamic studies, endoscopy, or in cases of inability to pass a catheter. The selection of patients for both subsequent imaging methods during the same visit was accidental, de-

pending on the availability of technical facilities, time, and radiologists.

First, we performed RUG, than SUG without complete disclosure of the results, and we finished both imaging methods with a radiographic film of voiding to avoid two installations of balloon catheter or a clamp.

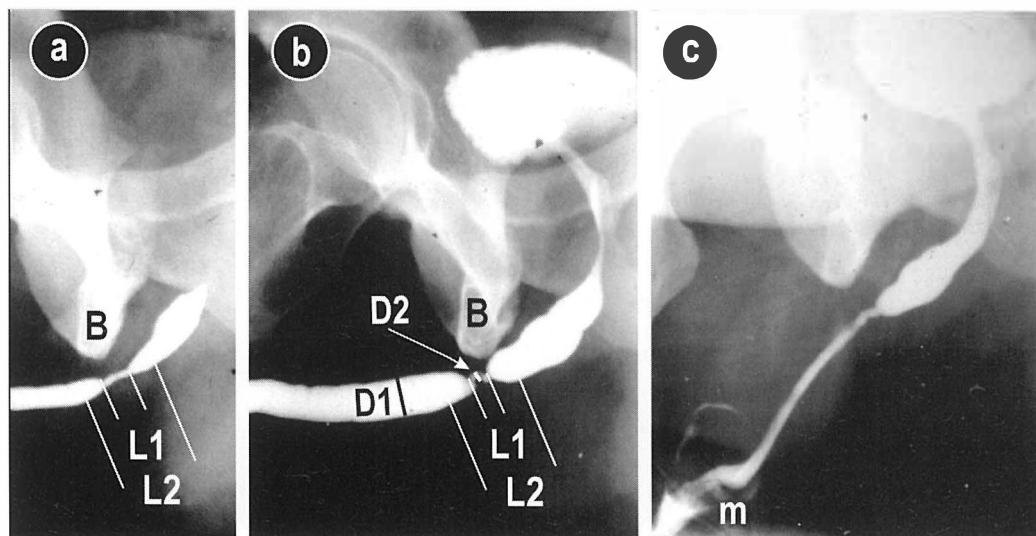
Dynamic RUG<sup>1,2,11</sup>, with retrograde contrast application under fluoroscopy and voiding as an integral part of the study was performed on a Siemens Siregraph D-2 by the radiologist with the assistance of the radiographer. Adequate contrast application without additional trauma provides constant visualisation of the posterior urethra, the membranous part, bulbar conus and also secondary softer strictures in the presence of primary harder one. Sufficiently oblique position is necessary to avoid the superposition and not to overlook bulbar strictures (Figure 1,2,3). We slightly modified standard RUG. We did not make AP film. We prefer two different oblique films usually with different quantity of contrast application for better length measurements and delineation of soft-er secondary strictures (Figure 3).

The duration of radiourethrography with the aseptic installation of devices for contrast application, hence without voiding, was approximate 20 minutes with the varying voiding time.

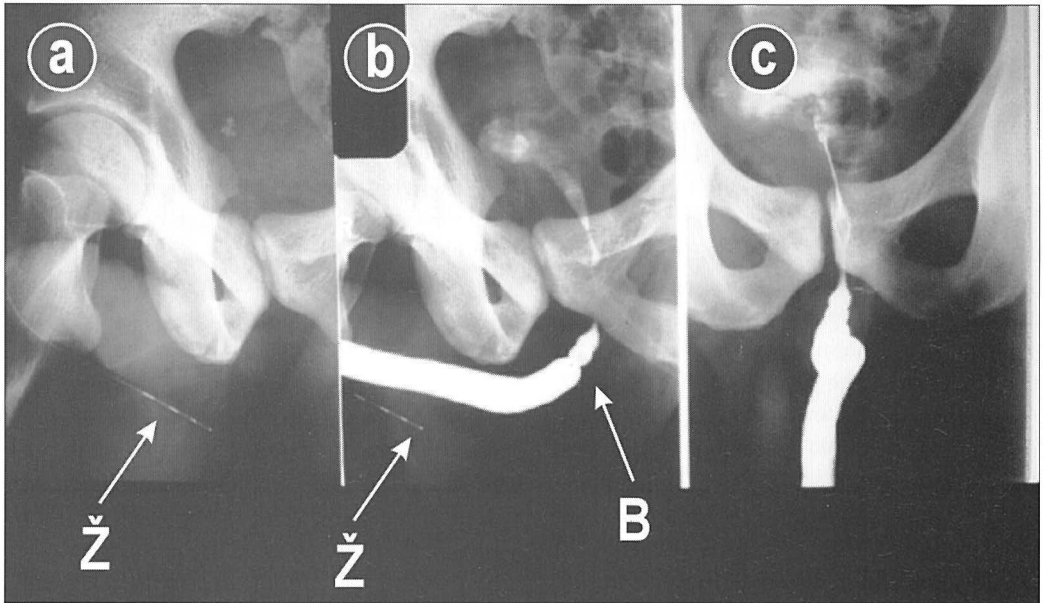
The whole urethra delineation is diagnostically important for recognition of all strictures and their precise localisation. Measurements are made from the films, and other observations are detected also during fluoroscopy. Such measurements and technical mistakes may be re-checked from the films also later.

In length measurements, we included tapering on both sides, "conning-down", and not only the length of a tight stricture. The degree of stricture was determined from anteroposterior diameter of the strictured area compared to the normal luminal diameter (Figure 1,3). The strictures were classified by Devine as: mild- less than a third, moderate-a third to half, and severe - more than half of the lumen reduction.

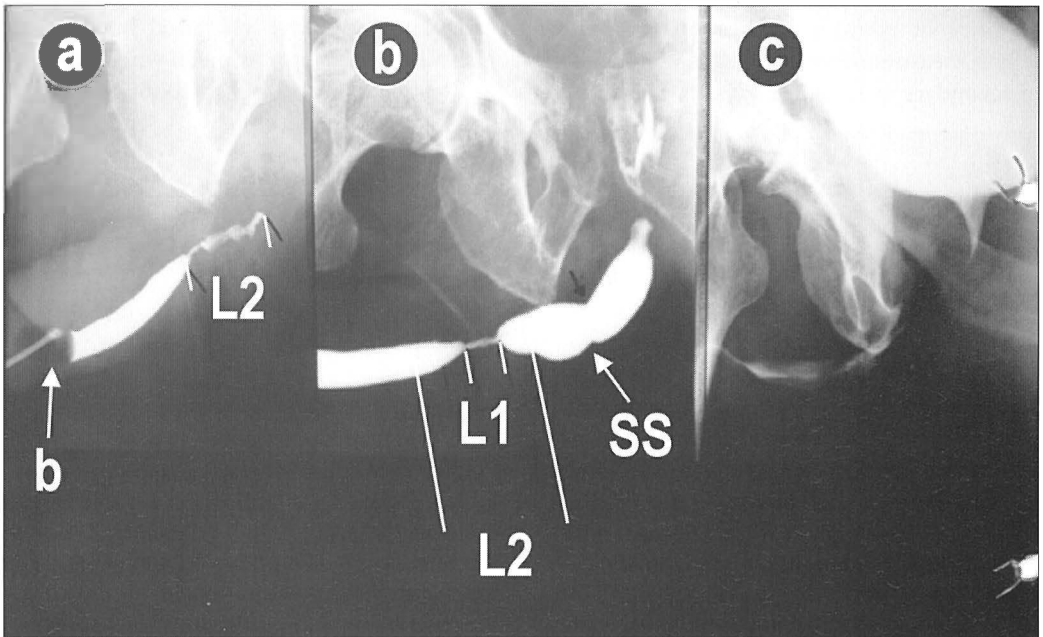
For objectivation of radiographic magnification in our study, we placed Lunderquist wire vessel measures or metal wires on penis in 7 patients, and analysed 10 different mea-



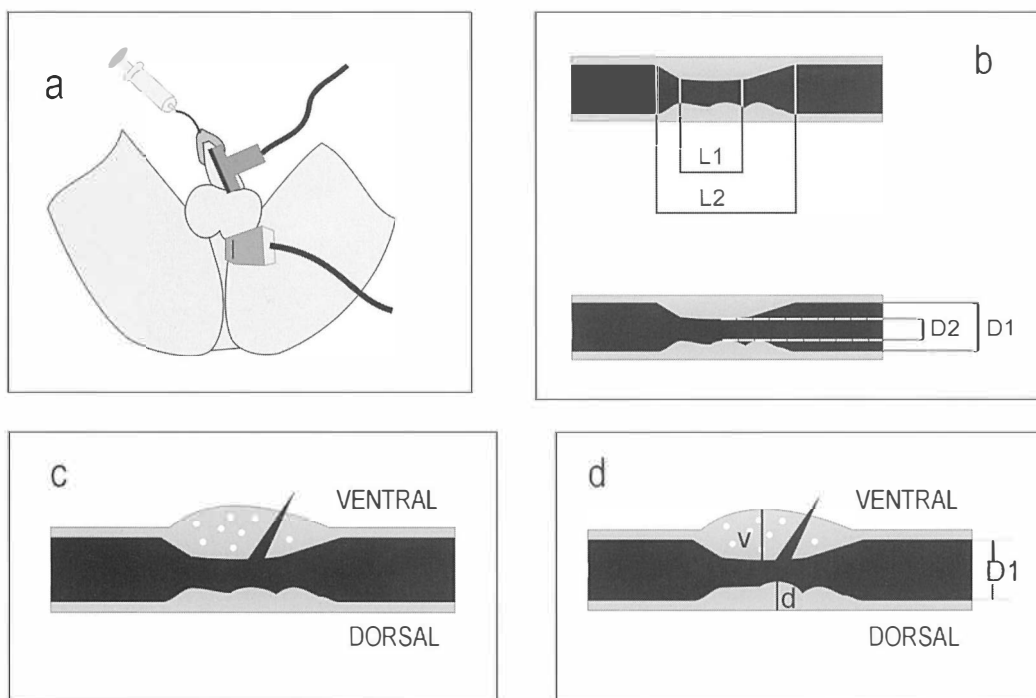
**Figure 1.** Radiographic urethrography(RUG)- evaluation of the stricture and measurements; a) Less contrast application, b) More contrast application, c) During voiding. B-bulbar stricture, L2-the length of the whole stricture, L1-the length of a tight stricture, D1-normal diameter, D2- reduced lumen, m- suspected meatal stricture.



**Figure 2.** Radiographic urethrography (RUG); a,b) Correct oblique position, c) AP position with superposition of bulbar urethra. B-bulbar stricture, ž-wire measure.



**Figure 3.** Radiographic urethrography(RUG); a) Less contrast application, b)More contrast application. L2-the length of the whole stricture, L1-the length of a tight stricture, SS- secondary soft stricture, b-baloon of the urethral catheter.



**Figure 4.** Evaluation of the stricture; a) Sonographic urethrography(SUG)-transducer position b) The length and diameter, c-d) Ventral(v) and dorsal(d) spongy changes and expansion outside spongiosum. L2-The length of the whole stricture, L1- the length of a tight stricture, D1- normal diameter, D2-reduced diameter.

surements, which varied depending on patients' constitutions and different oblique positions (Figure 2).

Sonourethrography, according to Mc Anninch, which was slightly modified from the first report in 1988, was performed by sonologist with the assistance of radiologist on Siemens Sonoline SI-400 and Toshiba SSA-270 A with 7.5 MHz linear probe placed ventrally on penis. Transcrotally and for perineal approach, we used also convex 3.75 MHz probe.

Multiple transverse and longitudinal measurements with electronic caliper were made (Figure 4) during constant adequate application of saline solution, but avoiding too much transducer compression. In selected patients, additional application of sonographic contrast Levovist was used for better delineation (Figure 5,6). The duration of sonography, when devices for contrast application were already installed at radiourethrography, ran-

ged from 20 to 40 minutes. The evaluations of a stricture presence, number location and measurements were made by the sonologist.

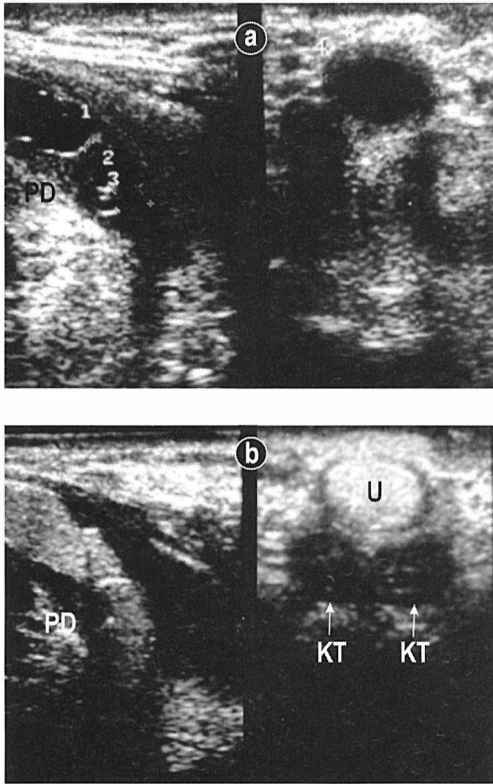
Normally, 20 ml of saline solution was sufficient, sometimes requiring up to 40ml. In selected patients, we used also 4 ml of sonographic contrast Levovist.

Measurements and technical mistakes are usually performer-dependant, sometimes impossible to detect and correct later.

Descriptive analyses and Wilcoxon non-parametric test were made in SPSS program for Windows.

## Results

Six patients had normal urethra diagnosed by both imaging techniques, and others had 70 strictures by RUG and 59 by SUG. Ten separated strictures by RUG were considered as 5



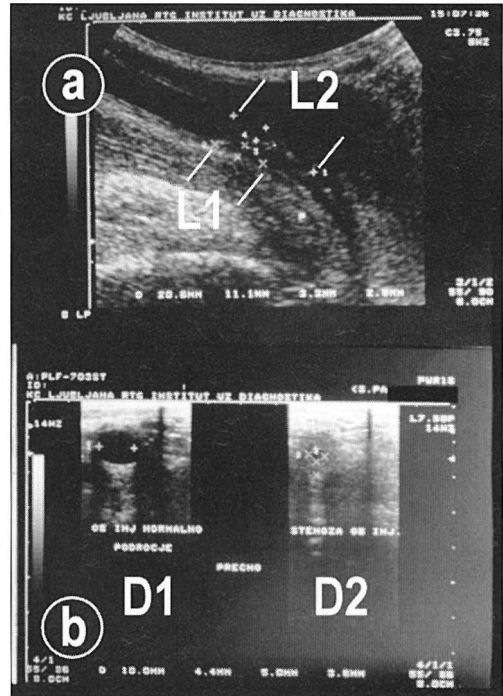
**Figure 5.** Sonographic urethrography(SUG)- longitudinal and transversal scans; a) Application of saline solution, b) Application of sonographic contrast Levovist. U-urethral lumen, PD-dorsal periurethral fibrosis, KT-corpus cavernosus.

strictures by SUG, and were measured together in the same or separated anatomical region, and caused differences in number and site of strictures. Sonography really missed 6 strictures; 5 meatal and one penile (Figure 7).

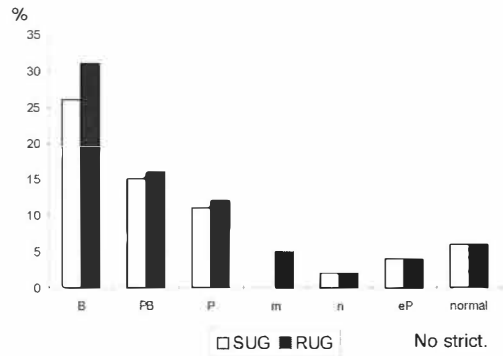
In contrast to previous reports, the radiographical lengths were 22 % longer than sonographical (Figure 8), and we did not find any significant differences neither in the lumen reduction (Figure 9) nor in Devine classification (Figure 10).

Radiographic magnification present in all measurements was proved by wire measurements (25 %).

Valuable additional sonographic evaluations were direct delineation and measure-

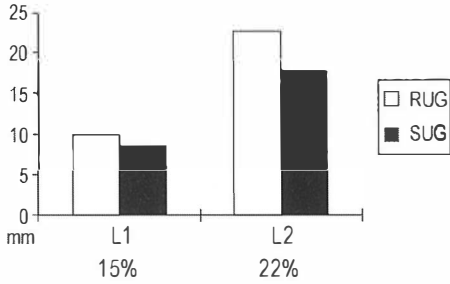


**Figure 6.** Sonographic urethrography-measurements of strictures; a) Longitudinal scan, b) Transverse scans. L2-the whole length, L1-the length of a tight stricture, D1-normal diameter, D2-reduced diameter.

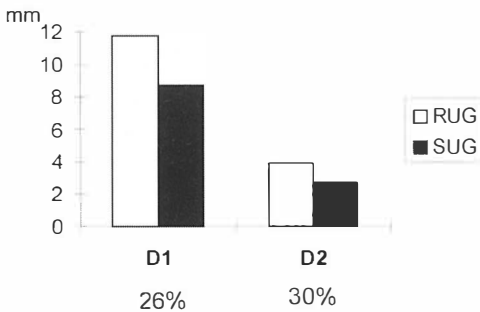


**Figure 7.** The location of strictures found by sonography (SUG) and radiography(RUG). B-bulbar, PB-penobulbar, P-penile, m-meatal, n-navicular, eP-entire penile, normal.

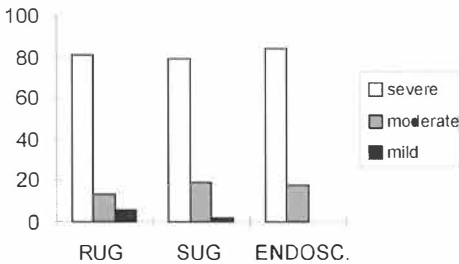
ments of the depth of spongiofibrosis observed ventrally deeper in 55.7 % of strictures (Figure 4cd,5,11), and suspected outside spongiosum expansion in 31 %.



**Figure 8.** Mean length of strictures found by sonography (SUG) and radiography (RUG). The percent of radiographic magnification. L1-the length of a tight stricture, L2-the entire stricture length.



**Figure 9.** Mean normal urethral lumen (D1) and reduced lumen (D2) found by sonography (SUG) and radiography (RUG). The percent of radiographic magnification.



**Figure 10.** Devine classification of urethral strictures by radiography (RUG), sonography (SUG), and endoscopy (endosc.).

Treatment decision, based on clinical symptoms, imaging, surgeon routine and experiences, differed from the proposed by our imaging technique in 82%; internal urethroto-my was made instead of reconstructive surgery and observed recurrence was 62%.

## Discussion

Until recently, the purpose of urethrography was to delineate the primary stricture and to describe the length of a tight stenosis. Such incorrect measurements could be the reason for published radiographic underestimation compared to sonography. Especially when radiourethrography is statically performed (without fluoroscopy) or modified voiding against Zipser clamp is evaluated, as it is obvious from previous reports, only a tight stricture is measured. We avoid static urethrography, which may contribute to the underestimation of length and grade and, consequently, also to inappropriate treatment decisions.<sup>7,11</sup>

In static urethrography, the membranous urethra is not usually visualised, and only the primary stricture is recognised. In a significant number of patients, secondary soft scars proximal to the primary stricture cannot be diagnosed in the fully distended urethra, because of paradoxical dilatation at urethrography or during voiding.<sup>11</sup> Consequently, such an improper comparison of two different lengths, the radiographic length of a tight stricture only without tapering on both sides and the sonographically directly visible entire length of wall changes, is therefore a misconception, leading to wrong conclusions (Figure 12). In such improper comparisons, we also found similar radiographic length underestimation in our patients, as mentioned in previous reports. SUG lengths in such wrong comparisons were for 78% longer than RUG.

By correct dynamic urethrography with voiding, we evaluated the whole stricture involvement and by accurate localisation of the membranous urethra also proximal strictures. Elongated, narrowed, irregular or asymmetric bulbar conus with presence of primary bulbar stricture (Figure 13), represents its extension to membranous part and indicates transsphincter urethroplasty.<sup>11</sup> Proper oblique patient's position, proper contrast application during exposure, voiding and cor-

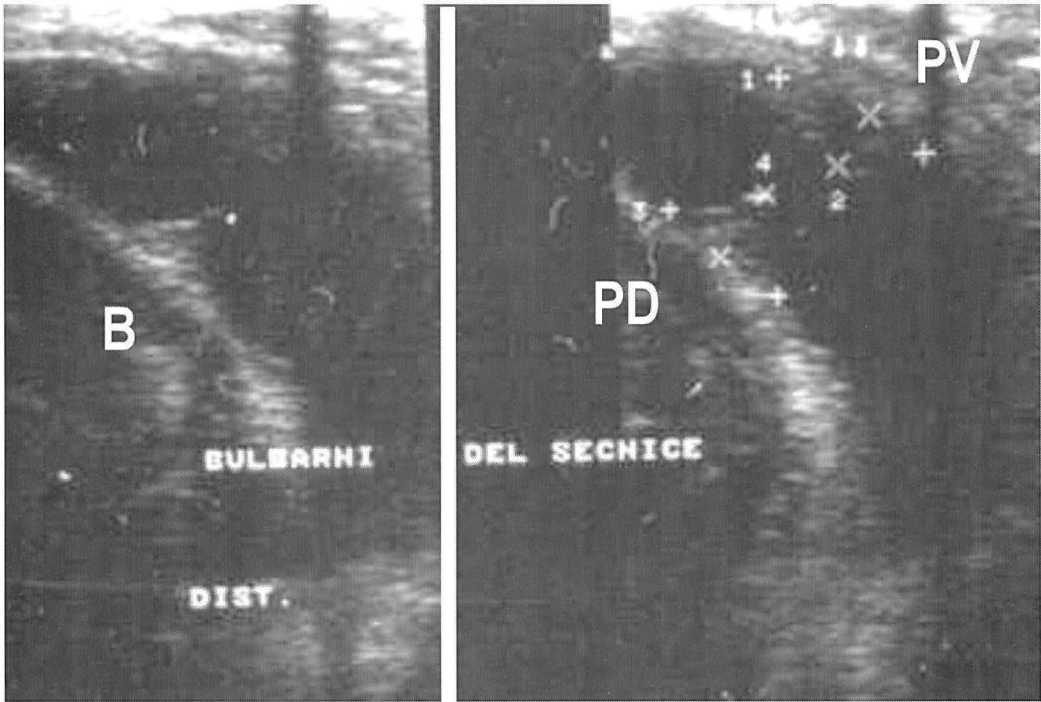


Figure 11. Sonographic urethrography-measurements of the periurethral changes ventrally (PV), and dorsally (PD).

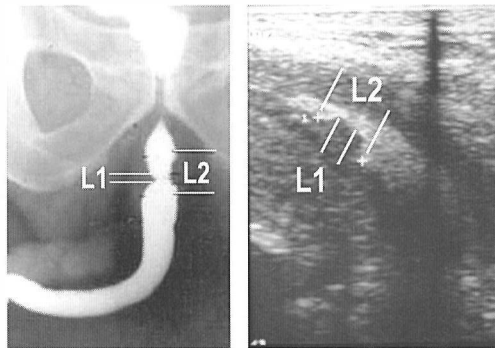


Figure 12. Radiographic and sonographic appearance of the same stricture. (Different degree of photographic magnification - direct length comparison is impossible). L1-the length of a tight stricture, L2-the whole length of the stricture.

rect measurement of the stricture length, the tight stricture with “conning down” segment which illustrates its involvement in the scar, contribute to better evaluation of the stricture as well as better treatment outcome. At the same time, we can observe primary hard

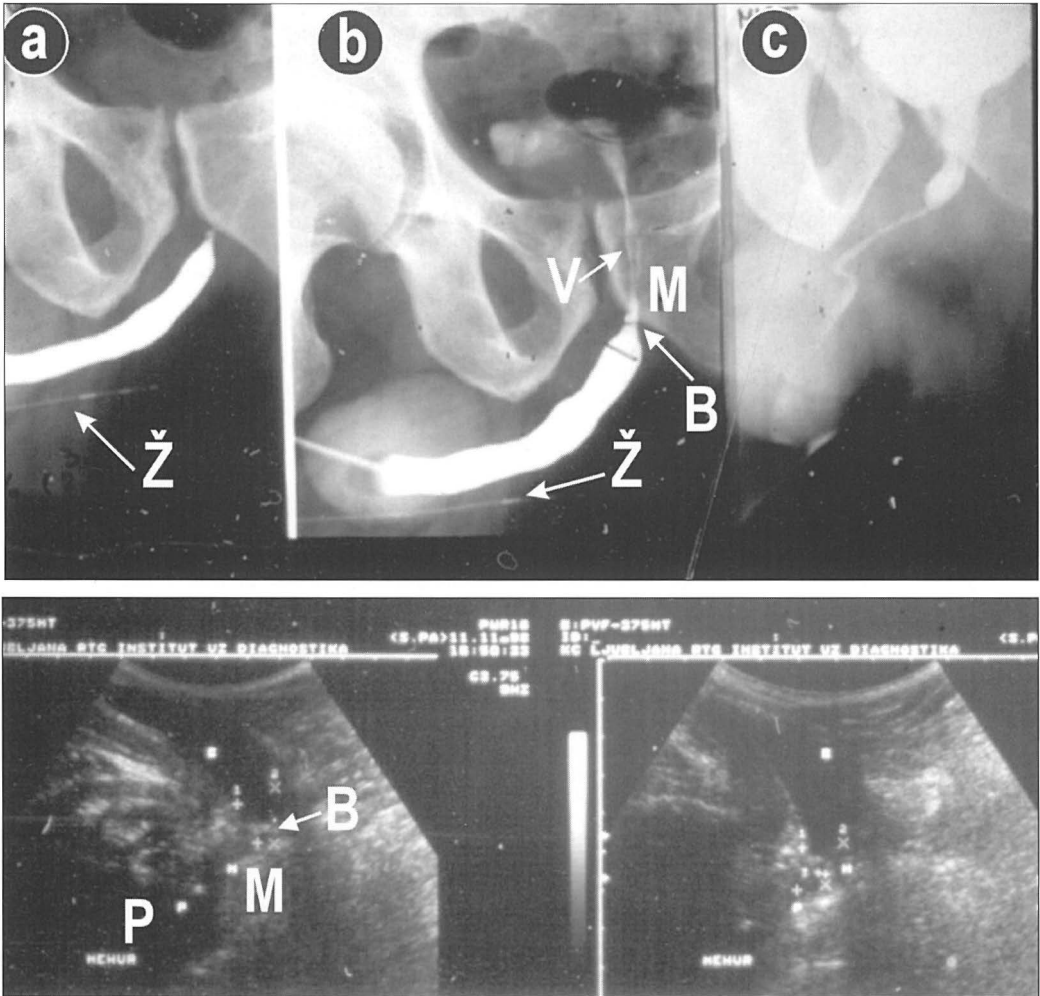
stricture with obstructive symptoms, and secondary softer ones without symptoms of outlet obstruction. The latter could contract and produce obstruction after surgical treatment of primary stricture alone.<sup>1,11</sup>

Our prediction that previously published radiographic length underestimation could be only interpretation mistake is proved by our results. RUG magnification affects equally measurements of urethral lumen diameter at normal and reduced sites of the same patient, and was present in wire measurements.

Until recently, the majority (95 %) of strictures were treated with one or more urethrotomies, either blindly (Otis method) in strictures with wide calibre, or under direct vision (Sachse method). Reported recurrences after urethrotomy were from 15 % up to 75 % or even 92 % in selected patients.<sup>4,12,13,14</sup>

According to the findings of a significant trend for radiographic length underestimation, the reported additional or better sono-





**Figure 13.** Evaluation of bulbar stricture (B) with suspected extension to membranous part (M) near prostatic portion (P) by radiography (a,b,c) and sonography.

graphic evaluations of urethral strictures compared to radiourethrography, changed urethrotomy to reconstructive surgery in 16%. According to other recent reports on sonography, the treatment changed, too: 33% of strictures were treated by urethrotomy and 63% by reconstructive surgery. In other reports, the reconstructive surgery was also changed after sonourethrography in 37%<sup>15</sup> of bulbar strictures with radiourethrographic intermediate length; graft or flap urethroplasty was made instead of end-to-end reconstruction.

Adding sonographic evaluation of the stricture length, lumen reduction and classification to radiourethrography there was no need to change treatment to more reconstructive surgery in our study. According to recent literature, the majority had been already indicated by radiographic results, based on our performance, described measurements, and interpretations. Different surgeons' decisions were the result of their experience and doctrine and is not based entirely on our imaging evaluations.

Considering mean 22% radiographic magnification and longer strictures found by RUG, that are contradictory to the published results, the study did not demonstrate any difference in measurements.

We can conclude that in everyday routine RUG is still the method of choice. We propose dynamic RUG by Mc Callum. Radiation-free SUG is valuable additional method with direct visualisation of the depth and quality of spongy changes. Sonography, detecting 92% of the strictures, may replace RUG, but in view of the sonologists-dependant mistakes, the combination of both imaging methods is optimal.

### References

1. Devine CJ Jr. Surgery of the urethra. In: Walsh PC, Gittes RF, Perlmutter AD, Stamey TA (editors). *Campbells urology*, 5th ed. Philadelphia: WB Saunders; 1986. p.2860-3.
2. Devine CJ Jr., Jordan GH. Surgery of anterior urethral strictures. In: Marshall FJ (editor). *Operative urology*. Philadelphia: WB Saunders; 1991. p. 307-21.
3. Merkle W, Wagner W. Sonourethrography of the distal male urethra - a new diagnostic procedure for urethral strictures: results of a retrospective study. *J Urol* 1988; **140**: 1409-11.
4. Merkle W, Wagner W. Risk of recurrent stricture following internal urethrotomy. Prospective ultrasound study of distal male urethra. *Br J Urol* 1990; **65**: 618-20.
5. Sakti D. Ultrasonographic evaluation of the urethral stricture disease. *Urology* 1992; **40**: 237-42.
6. Mc Anninch JW, Laing FC, Jeffrey RB Jr. Sonourethrography in the evaluation of urethral strictures: a preliminary report. *J Urol* 1988; **139**: 294-7.
7. Gluck CD, Bundy AL, Fine C, Loughlin KR, Ritchie JP. Sonographic urethrogram: comparison to roentgenographic techniques in 22 patients. *J Urol* 1988; **140**: 1404-8.
8. Gupta S, Manibrata B, Tiwari A, Gupta RK, Kumar A, Gujral RB. Sonourethrography in the evaluation of anterior urethral strictures: Correlation with radiographic urethrography. *J Clin Ultrasound* 1993; **21**: 231-9.
9. Nash PA, McAnninch JW, Bruce JE, Hanks DK. Sonourethrography in the evaluation of anterior urethral strictures. *J Urol* 1995; **154**: 72-6.
10. Morey AF, McAnninch JW. Ultrasound evaluation of the male urethra for assessment of urethral stricture. *J Clin Ultrasound* 1996; **24**: 473-9.
11. Mc Callum RW. The adult male urethra: normal anatomy, pathology and method of urethrography. *Rad Clin N Amer* 1979; **17**: 227-44.
12. Netto NR, Lemos GC, Claro JFA. Internal Urethrotomy as a complementary method after urethroplasties for posterior urethral stenosis. *J Urol* 1989; **30**: 50-1.
13. Hjordrup A, Sorensen C, Sanders S, Moesgaard F, Kirkegaard P. Strictures of the male urethra treated by the Otis method. *J Urol* 1983; **25**: 903-5.
14. Gibod LB, Portz BL. Endoscopic urethrotomy: does it live up to its promises? *J Urol* 1982; **127**: 433-5.
15. Morey AF, Mc Anninch J W. Role of preoperative sonourethrography in bulbar urethral reconstruction. *J Urol* 1997; **31**:1376-9.
16. Tanago EA. Surgical anatomy of genitourinary tract. In: Walsh PC, Gittes RF, Perlmutter AD, Stamey TA (editors). *Campbells urology*, 6th ed. Philadelphia: WB Saunders;1992: p. 50-8.