

## Concomitant radiotherapy and mitomycin C with bleomycin in inoperable head and neck cancer

Branko Zakotnik,<sup>1</sup> L. Šmid,<sup>2</sup> M. Budihna,<sup>1</sup> H. Lešničar,<sup>1</sup> E. Šoba,<sup>1</sup> L. Furlan,<sup>1</sup>  
M. Žargi<sup>2</sup>

<sup>1</sup> Institute of Oncology, <sup>2</sup> University Department of Otorhinolaryngology and Cervicofacial Surgery, Ljubljana, Slovenia

*In a prospective randomized study the efficacy of simultaneous irradiation with Mitomycin C and Bleomycin in patients with inoperable head and neck carcinoma was assessed. Between March 1991 and December 1994, 64 patients with inoperable head and neck carcinoma were randomly assigned to receive either radiation therapy alone (group A) or radiotherapy combined with simultaneous Mitomycin C and Bleomycin (group B). The disease-free survival (DFS) at 4 years for group B was 37%, and for group A 8%. ( $P=0.016$ ), and the overall survival (OS) was 26% for group B and 7% for group A ( $p=0.09$ ). The DFS for patients with oropharyngeal carcinoma in group B was 48% and in Group A 10% ( $p=0.0009$ ) and the OS was 38% in group B and 10% in group A ( $p=0.024$ ). In patients with nonoropharyngeal carcinoma, there were practically no differences in DFS and OS between groups B and A. The concomitant treatment (radiotherapy, Mitomycin C, Bleomycin) significantly improved DFS and OS in patients with oropharyngeal carcinoma.*

**Key words:** head and neck neoplasms-therapy; radiotherapy; bleomycin; mitomycin C; treatment outcome

### Introduction

During the past 20 years, the incidence of carcinoma of the oral cavity and pharynx has been increasing considerably in our country.<sup>1</sup> At diagnosis, more than half of the tumors are in advanced, inoperable stage. Various combinations of treatment modalities tested so far have failed to provide significant improvement of survival. Chemotherapy, applied as induction treatment has not yielded significant survival benefit.<sup>2</sup> In contrast to this, simultaneous application of combined radio- and chemotherapy has proved to be more effective in the treatment of advanced head and neck carcinomas.<sup>3-6</sup> Yet, the question of the most suitable chemotherapeutic combination still remains to be solved.<sup>7</sup>

The aim of our prospective randomized clinical study was to compare radiotherapy (arm A) and

radiotherapy combined with simultaneous application of Mitomycin C, Bleomycin, Nicotinamid, Chlorpromazine, and Dicoumarol (arm B).

### *Rationale for selection of chemotherapeutic scheme*

According to some basic experimental studies that bioreductive alkylating agent Mitomycin C is selectively toxic to radioresistant hypoxic cells<sup>8,9</sup> and considering clinical studies of Weisberg<sup>6</sup> and Dobrowsky,<sup>10</sup> it appears that its use in patients with advanced head and neck carcinoma is justified. Namely, in a majority of these patients, a high percentage of hypoxic cells due to large tumor mass can be expected. Since more than only additive effect of combination of Mitomycin C and irradiation was speculated,<sup>11,12</sup> we decided to apply Mitomycin C and two irradiation fractions (2 Gy each) in the same day, after patients had received a dose of 10 Gy. Some studies<sup>6,13</sup> indicate that the repeated application of Mitomycin C improves the treatment effect. In accordance with this observation, a re-

peated dose of Mitomycin C before the end of therapy was planned.

It seems that Dicoumarol significantly enhances the effect of Mitomycin C on hypoxic tumor cells.<sup>14</sup> Therefore, the application of Mitomycin C was combined with Dicoumarol. In contrast to Mitomycin C, Bleomycin prevaillingly acts on oxygenated cells. Due to its radiosensitizing effect, Bleomycin has been tested in several clinical studies.<sup>2,4,5,15</sup> In the treatment of carcinoma of the oral cavity, a simultaneous combination of irradiation and Bleomycin-based chemotherapy improved survival in some randomized studies.<sup>4,5</sup>

Some studies *in vitro* have confirmed the resistance of certain tumor cell lines to Bleomycin.<sup>16</sup> It seems possible that this resistance could be further enhanced by mutagens such as ionizing irradiation and Mitomycin C. In attempt to avoid the appearance of resistant cell lines, our patients received Bleomycin in combination with Nicotinamid, as suggested by the results of a corresponding basic study.<sup>16</sup>

According to the findings of Hait and coworkers<sup>17</sup> that simultaneous application of Bleomycin and Chlorpromazine significantly enhances the effect of Bleomycin on tumor cells and, at the same time, reduces the appearance of pulmonary fibrosis, Chlorpromazine was also incorporated in our chemotherapeutic scheme.

Combination of both, Mitomycin C and Bleomycin proved to be effective in the treatment of advanced squamous cell carcinoma of the cervix uteri.<sup>13</sup> The same cytotoxic drugs were used by Andreasson et al. in the treatment of advanced head and neck carcinomas. In this study, severe local adverse reactions due to intraarterial application of Mitomycin C were reported. Considering this, our patients were treated by intravenous application of Mitomycin C, while Bleomycin was given intramuscularly.

### Patients and methods

Between March 1991 and December 1994, 64 patients with previously untreated, histologically confirmed inoperable squamous cell carcinoma of the head and neck entered the study. The median age of patients was 51 years (range 37-68). Pretreatment assessment consisted of physical examination, endoscopy with biopsy, radiography of the head and neck with or without computerized tomography,

and ultrasonography of the neck and abdomen, complete blood count and blood biochemistry, diffusion for CO. For staging, the UICC staging criteria were used. Criteria for inoperability were technical unresectability and/or selection based on low surgical curability.<sup>4</sup> Eligibility criteria, determined by the multidisciplinary team of radiation oncologist, head and neck surgeon, and medical oncologist included performance status < 3 (WHO), Hb > 100 g/l, L > 3.5 x 10<sup>9</sup>/l, Tr > 100 x 10<sup>9</sup>/l, normal bilirubin, creatinin, prothrombine time, and diffusion for CO. Informed consent was obtained from all patients. Patients with distant metastases, previous or simultaneous other malignancy except cured skin carcinoma, psychotic and senile patients, and those refusing the proposed treatment were excluded from the study. Eligible patients were randomly assigned to one of the two treatment groups using randomization with permuted blocks and stratified according to primary tumor site (Table 1). Sixty patients had Stage IV and four Stage III of disease.

**Table 1.** Treatment by site (RT=radiotherapy, ChT=chemotherapy)

Site	RT	RT + ChT	All
paranasal sinuses	2	4	6
oral cavity	6	4	10
oropharynx	21	20	41
hypopharynx	3	4	7
All	32	32	64

All patients in both groups received fractionated irradiation five times weekly with 2 Gy to the total dose of 66-70 Gy to the gross disease and 50 Gy to the clinically negative regions of the neck and supraclavicular lymph-node areas. On the day of the first application of Mitomycin C, patients in group B were treated with two fractions of 2 Gy with an interval of at least 6 h in between. The radiation dose to the spinal cord was 40 Gy.

Chemotherapy regimen included intramuscular application of Bleomycin 5 units twice a week with the planned total dose being 70 units and Mitomycin C 15 mg/m<sup>2</sup> given intravenously after delivery of 10-12 Gy of irradiation. The application of Mitomycin C was planned to be repeated on the last day of radiotherapy in a dose of 10 mg/m<sup>2</sup>. Throughout the therapy, patients in group B received Nicotinamid (650 mg/day) and Chlorpromazine (200 mg with Bleomycin). Dicoumarol (300 mg) was applied in the evening and morning before Mitomycin C.

The main endpoints of the trial were tumor response, toxicity, disease-free survival (DSF), and overall survival (OS). The response rate was estimated 2 months after therapy. The difference in response rates was tested with X<sup>2</sup> test. If the number of patients was less than 5 in any cell of the table, a Fischer exact test was used. The survival was calculated after the completed treatment using the method of Kaplan - Meier and a logrank test was used to test the differences between groups.

**Results and conclusions**

All 64 patients who had entered the study, were evaluable for tumor response, toxicity, DFS and OS. Median follow-up was 42 months (range 21 - 63 months). Table 2 shows tumor response 2 months after treatment.

**Table 2.** Response rates in all, oropharyngeal and nonoropharyngeal carcinoma patients (RT=radiotherapy, ChT=chemotherapy, CR=complete remission)

All patients	RT	RT + ChT	p
CR	10 (31%)	19 (59%)	
not CR	22 (69%)	13 (41%)	0,04
<hr/>			
Oropharynx			
CR	6 (29%)	15 (75%)	
not CR	15 (71%)	5 (25%)	0,007
<hr/>			
Others			
CR	4 (36%)	4 (33%)	
not CR	7 (64%)	8 (67%)	0,33

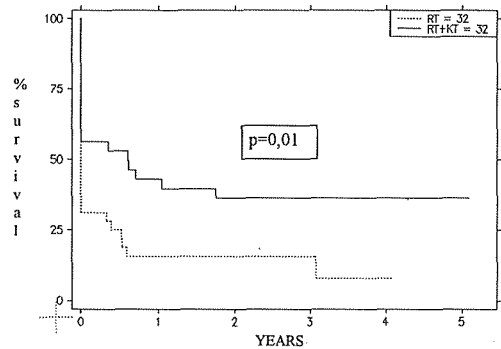
There was no treatment related death. The frequency and severity of early toxic effects due to therapy were more pronounced in patients in treatment group B (Table 3) and sometimes the dose reduction of Bleomycin and/or Mitomycin C was necessary, while there was no reduction of the total irradiation dose.

**Table 3.** Incidence of toxic side-effects by WHO toxicity grade (RT=radiotherapy, ChT=chemotherapy)

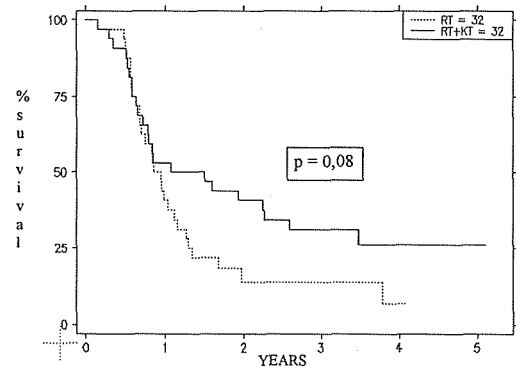
Grade		0	1	2	3	4
mukositis	RT	0	2	11	17	2
	RT+ChT	0	1	3	13	15
infection	RT	30	1	0	1	0
	RT+ChT	19	5	4	4	0
leucopenia	RT	31	1	0	0	0
	RT+ChT	18	8	5	1	0

Eight patients underwent salvage surgery, 2 from group A and 6 from group B. Surgery was successful in two group B patients only.

The DFS for group B was 37%, and for group A 8%. (P=0.01) (Figure 1), and the OS was 26% for group B and 7% for group A (p=0.08)(Figure 2). The DFS in patients with oropharyngeal carcinoma in group B was 48% and in Group A 10% (p=0.001) (Figure 3) and the OS was 38% in group B and 10% in group A (p=0.019) (Figure 4). In patients with nonoropharyngeal carcinoma, there were practically no differences in DFS and OS between groups B and A.

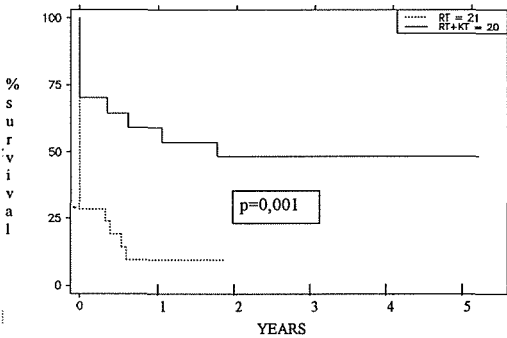


**Figure 1.** Disease free survival in all patients (RT=radiotherapy, KT=chemotherapy).

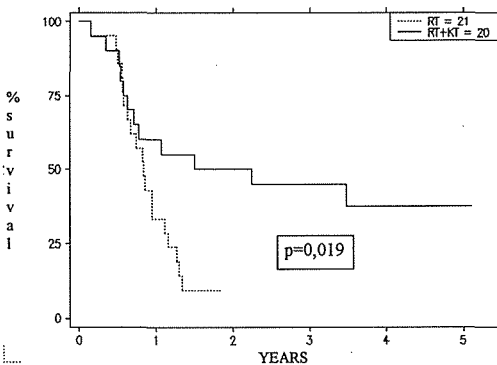


**Figure 2.** Overall survival in all patients (RT=radiotherapy, KT=chemotherapy).

From our study it seems that concomitant radiochemotherapy improves survival significantly in patients with inoperable oropharyngeal squamous cell carcinoma. Although the number of patients with nonoropharyngeal carcinoma is rather small, it



**Figure 3.** Disease free survival of patients with oropharyngeal carcinoma (RT=radiotherapy, KT=chemotherapy).



**Figure 4.** Overall survival of patients with oropharyngeal carcinoma (RT=radiotherapy, KT=chemotherapy).

seems that this concomitant treatment modality is not profitable for these patients.

The intent of our concomitant treatment was to achieve a higher percentage of complete response rates and better survival by enhancing the effect of radiotherapy with several additional drugs. The prevalence of complete responders and improved survival in the combined therapy group is therefore not the consequence of only one, but probably of several coexisting factors.

The choice of chemotherapeutic agents used in our trial was done on the basis of their effectiveness on hypoxic tumor cells, as well as their radiosensitizing effect. The latter is believed to be responsible for marked acute mucositis in patients treated by combined therapy.

## References

1. Cancer Registry of Slovenia. Cancer incidence in Slovenia 1990. Ljubljana: Institute of Oncology, 1993.
2. Auersperg M, Šoba E, Vraspir-Porenta O. Intravenous chemotherapy with synchronization in advanced cancer of oral cavity and oropharynx. *Z Krebsforsch* 1977; **90**: 149-59.
3. Adelstein DJ, Vishawa MS, Scott E. Simultaneous versus sequential combined technique therapy for squamous cell head and neck cancer. *Cancer Res* 1990; **65**: 1685-91.
4. Fu KK, Phillips TL, Silverberg IJ et al. Combined radiotherapy and chemotherapy with bleomycin and methotrexate for advanced inoperable head and neck cancer: update of Northern California oncology group randomized trial. *J Clin Oncol* 1987; **5**: 1410-8.
5. Shanta V, Krishnamurti S. Combined therapy of oral cancer with bleomycin and radiation: a clinical trial. *Clin Radiol* 1977; **28**: 427-9.
6. Weissberg JB, Son YH, Papac RJ et al. Randomized clinical trial of mitomycin C as an adjunct to radiotherapy in head and neck cancer. *Int J Radiat Oncol Biol Phys* 1989; **17**: 3-9.
7. Vokes EE. Interactions of chemotherapy and radiation. *Semin Oncol* 1993; **20**: 70-9.
8. Kennedy KA, Rockwell S, Sartorelli AC. Preferential activation of mitomycin C to cytotoxic metabolites by hypoxic tumor cells. *Cancer Res* 1980; **40**: 2356-60.
9. Vokes EE, Weichselbaum RR. Concomitant chemoradiotherapy: rationale and clinical experience in patients with solid tumors. *J Clin Oncol* 1990; **8**: 911-34.
10. Dobrowsky W. Unconventional fractionation with or without mitomycin C in advanced head and neck cancer. *Semin Oncol* 1992; **2**: 45-7.
11. Dobrowsky W, Dobrowsky E, Rauth AM. Mode of interaction of 5-fluorouracil, radiation and mitomycin C: in vitro studies. *Int J Radiat Oncol Biol Phys* 1992; **22**: 875-80.
12. Von der Maase H, Overgaard J. Interactions of radiation and cancer chemotherapeutic drugs in a C3H mouse mammary carcinoma. *Acta Radiol Oncol* 1985; **24**: 181-7.
13. Miyamoto T, Takabe Y, Watanabe M, Terasima T. Effectiveness of sequential combination of bleomycin and mitomycin C on an advanced cervical cancer. *Cancer* 1978; **41**: 403-14.
14. Rockwell S, Keyes SR, Sartorelli AC. Modulation of the antineoplastic efficacy of mitomycin C by dicoumarol in vivo. *Cancer Chemother Pharmacol* 1989; **24**: 349-53.
15. Eschwege F, Sancho-Garnier H, Gerard JP. Ten-year results of randomized trial comparing radiotherapy and concomitant bleomycin to radiotherapy alone in epidermoid carcinoma of the oropharynx: experience of the European Organization for Research and Treatment of Cancer. *NCI Monogr* 1988; **6**: 275-8.

16. Urade M, Sugi M, Mima T. High induction of poly (ADP-ribose) polymerase activity in bleomycin resistant hela cells. *Jpn J Cancer Res* 1989; **80**: 464-8.
17. Hait WN, Lazo JS, Chen DL, Gallichio VS, Filderman AE. Antitumor and toxic effects of combination chemotherapy with bleomycin and anticalmodulin agent. *J Natl Cancer Inst* 1988; **80**: 246-50.