

ELECTROCHEMOTHERAPY COMBINED WITH STANDARD AND CO₂ LASER SURGERIES IN CANINE ORAL MELANOMA

Julita Kulbacka^{1*}, Joanna Paczuska², Nina Rembiałkowska¹, Jolanta Saczko¹, Zdzisław Kiełbowicz², Wojciech Kinda², Bartłomiej Liszka², Małgorzata Kotulska³, Bor Kos⁴, Damijan Miklavčič⁴, Nataša Tozon⁵, Maja Čemažar⁶

¹Department of Medical Biochemistry, Medical University of Wrocław, Chałubińskiego 10, 50-368 Wrocław; ²Department of Surgery, Wrocław University of Environmental and Life Sciences, Norwida 31, 50-375 Wrocław; ³Department of Biomedical Engineering, Faculty of Fundamental Problems of Technology, University of Science and Technology, Wrocław, Wybrzeże Wyspiańskiego 27, 50-370 Wrocław, Poland; ⁴Faculty of Electrical Engineering, University of Ljubljana; Tržaška 25; ⁵Small Animal Clinic, Veterinary Faculty, University of Ljubljana, Cesta v Mestni log 47; ⁶Institute of Oncology Ljubljana, Zaloška 2, 1000 Ljubljana, Slovenia

*Corresponding author, E-mail: julita.kulbacka@umed.wroc.pl

Abstract: Oral melanomas commonly occur in elderly dogs resulting in darkly pigmented areas of the mouth, tongue and gums. The main object of this study was a severe melanoma diagnosed in the jaw of a 15-year-old dog and its palliative treatment with electrochemotherapy. The tumour spread throughout the jaw including bones. Electrochemotherapy (ECT) with bleomycin and calcium solution (CaCl₂) was combined with standard and CO₂ laser surgeries. The treatment resulted in good local control of the tumour mass after one ECT session with bleomycin and a second ECT session with calcium ions solution. ECT significantly reduced bleeding and enhanced success of the surgery. The combination of ECT with surgical debulking resulted in rapid recovery and regaining of physiological activities, including normal feeding by the dog.

This case demonstrates that the protocol combining ECT and surgery is promising in palliative melanoma treatment.

Key words: oral melanoma; CO₂ laser; electrochemotherapy; bleomycin; calcium ions

Introduction

Oral melanomas remain a therapeutic problem in veterinary medicine. Localization of the tumour in the oral cavity often results in late detection and advanced neoplastic process at the time of diagnosis. The average lifespan of a dog with oral melanoma depends on the biological behaviour of the tumour and its clinical stage at the moment of diagnosis. However, compared to dogs with melanomas localized in other regions, those

with oral melanomas have the shortest survival times, ranging from 2 to 14 months (1-3). Typical treatment requires an aggressive local intervention for tumour control, usually accompanied by a wide surgical excision, sometimes involving partial mandibulectomy or maxillectomy (1). Early metastasis, in most cases before the time of diagnosis, and tumour recurrence are common in cases of oral malignant melanomas. Because the chances of cancer recurrence and rapid metastasis are very high, chemotherapy, immunotherapy, local and/or systemic adjuvant treatment, radiotherapy or electrochemotherapy (ECT) should be considered (3). Previous studies

indicate that ECT with cytostatics is an effective treatment for various tumours in animals, and ECT is quite a simple method with short treatment sessions, low chemotherapeutic doses and insignificant side effects (4, 5). Here, we present a case of malignant oral melanoma treated with ECT during surgery in the Department of Surgery of Wrocław University of Environmental and Life Sciences in Wrocław, Poland.

Case presentation

A 15-year-old male crossbreed dog (weight 30 kg) was diagnosed with stage IV malignant melanoma of the oral cavity with involvement of the mandibular bone. The tumour mass infiltrated the entire left mandibular body tissue (Fig.1 A).

Deformation of the facial area, difficulties in food intake, halitosis, drooling, and occasional bleeding had been observed by the owner for approximately 2 months. The patient could not be properly diagnosed by a veterinarian due to the dog's aggressiveness and concerns by the owner about sedation risk. RTG and CT indicated enlarged and distorted mandibular lymph nodes on the left side of the jaw. A large mass was located in the sublingual area and over the left mandibular body with local osteolysis of the bone. Histopathologic examination of a biopsy taken from the enlarged lymph node and oral tumour revealed malignant melanoma. The patient was diagnosed with stage IV of the disease with metastatic spread. A week after the first examination, the dog was unable to eat and the owner chose and approved the palliative treatment.

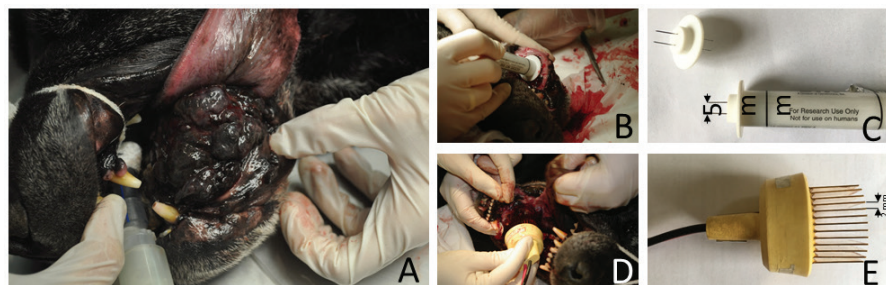


Figure 1: Oral melanoma in dog: A) The tumour in the mandible of the dog; B) two-needle array electrode during electrochemotherapy (ECT); C) disposable two-needle array tips; D) Petri Pulsar during ECT; E) Petri Pulsar electrode

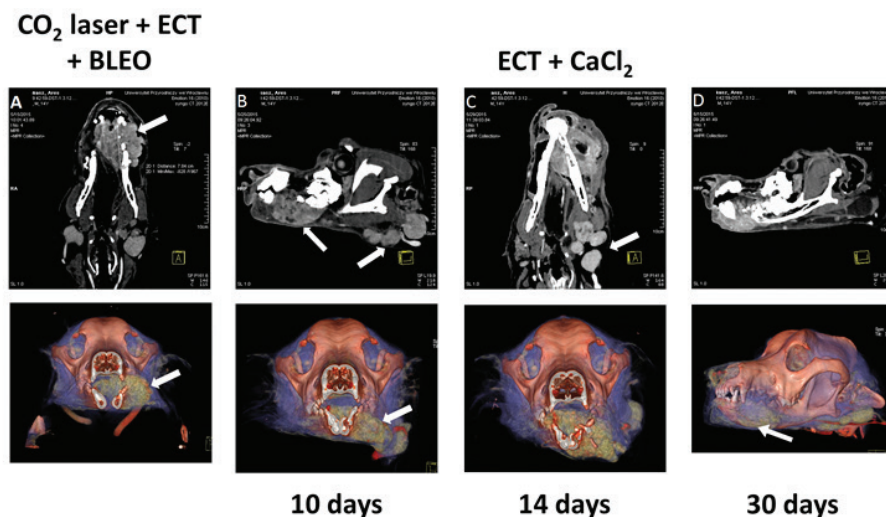


Figure 2: CT imaging before and after therapy. In the lower panel tumour mass tissue is represented in yellow-green colour and the tumour is indicated by white arrows: A) day of ECT; B) 10 days after ECT; C) 14 days after ECT; D) 30 days after last ECT session

Table 1: The detailed data of tumour mass before, during, and after treatment

Days after ECT	Width [cm]	Height [cm]	Length [cm]	Estimated tumour volume [cm ³]
day of ECT	7.07	4.83	7.84	140.11
10 days	6.05	2.95	6.71	62.67
14 days	7.95	3.40	8.68	122.78
30 days	6.55	2.70	6.40	59.23

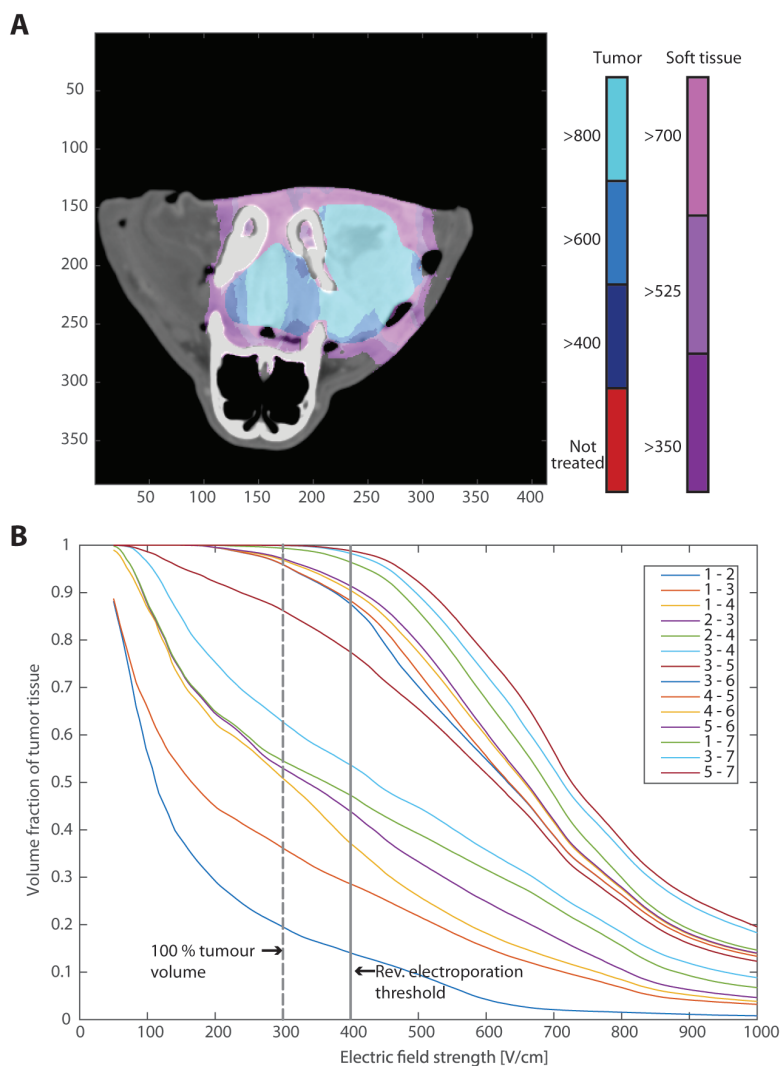


Figure 3: Electroporation field distribution modelling results from Visifield (8). A) The electroporation cross-section shows a representative slice and the local electric field coverage. B) Dose-volume histogram showing the cumulative coverage of the tumour with electric field. After the delivery of all pulses the whole tumour volume is covered with at least 300 V/cm electric field

Surgery-ECT treatment

The dog was examined from April to September of 2015. It was premedicated intramuscularly with medetomidine 0.3 ml (cepetor 1 mg/ml, ScanVet) and midazolam 0.6 ml (midanium 5mg/ml, Polfa S.A.). General anaesthesia was induced with 3 ml of propofol (scanofol 10 mg/ml, ScanVet) and after intubation with a 9 mm diameter cuffed tube, anaesthesia was maintained with isoflurane (aerrane, Baxter). Proper analgesia was assured during the surgery by infusion of fentanyl at a constant rate of 0.2 µg/kg/min (fentanyl WZF 50 µg/ml, Polfa Warsaw). Debulking of the tumour tissue was performed using a CO₂ laser with 0.25 mm spot diameter, 12 W power output, in a continuous wave mode. Coagulation with 1.4 mm spot diameter was insufficient and bleeding from the remaining tissue occurred. ECT

included intravenous (i.v.) and intratumoural (i.t.) administrations of bleomycin (Bleomedac, medac Gesellschaft für klinische Spezialpräparate mbH) and exposure of the remaining tumour mass to the electric pulses. Bleomycin was dissolved in physiological saline and applied at a concentration of 0.3 mg/kg i.v. and at 3 mg/ml i.t. (total dose 4 ml). Bleomycin was applied by both i.v. and i.t., because of the very irregular shape of the tumour tissue and visible fragments of the remaining tissue that could not be surgically removed. The interval between i.v. and i.t. bleomycin administration and the application of electric pulses was 8 minutes. Electroporation was performed using an ECM 830 Square Wave Electroporation System (BTX Harvard Apparatus, purchased from Syngen Biotech, Poland). Two types of electrodes were used: 1) two-needle array (BTX model 532) (Fig.1 B and C) and 2) Petri Pulser Electrode (BTX model

45-0130) (Fig.1 D and E). In the two-needle array electrode, the needle spacing was 5 mm with a needle length of 20 mm. The needles were made of stainless steel and were attached to a handle 8 cm long. The Petri Pulser electrode consisted of 13 gold plated electrodes with needle diameter 0.5 mm and gap size 2 mm. In each application of electrodes, 8 square wave pulses of 100 μ s each were delivered at 1 Hz, with the voltage-to-distance ratio set at 1300 V/cm (302 V for Petri Pulser electrode and 650 V for the needle array electrodes). After the treatment, the dog remained in the clinic for about 2 hours. It was examined daily for the first 3 days, then every week to evaluate the treatment effectiveness and possible local and systemic side effects. Standard and 3D CT imaging of the dog's mandibula before and after therapeutic procedures are presented in Fig. 2.

ECT enhanced the surgical effect, stopped bleeding during surgery and enabled rapid recovery of physiological activities. The day after the surgery the owner reported that the dog resumed eating. After 10 days the tumour mass decreased in visible areas of the local necrosis and no bleeding from the remaining tissue was observed. Enlargement of the mandibular lymph nodes and difficulty in swallowing were noted 14 days after the first ECT, and CT revealed enlargement of the metastatic spread in the lymph nodes along with swelling of the treated area (Fig. 2C and Tab.1). On that day ECT with calcium ions (CaCl_2 in low concentration at 5 mM, 10 ml delivered i.t.) was performed directly on the metastasis in the lymph nodes and on the remaining tumour mass. Only two-needle array electrodes were used and in each application the electric field was 8 square wave pulses of 100 μ s each, delivered at 1 Hz and a voltage of 650 V. After 5 days strong inflammation occurred in the lymph nodes and during the next two days dexamethasone (0.1 mg/kg per day) was applied. The dog was examined on the 30th day after the second treatment and no metastases in the lymph nodes were observed (Fig.2 D). These observations may indicate that treatment with calcium ions, which induced strong inflammation, led to additional immune response. Unfortunately, the dog began to have seizures 2 months after the primary diagnosis, probably due to metastatic spread in the brain, prompting the owner to choose euthanasia.

Treatment planning

This case was treated by electrochemotherapy during surgery using fixed geometry electrodes. However, after conclusion of the case we investigated the possibility of using single needle electrodes of variable geometry in combination with computational treatment planning. This post-treatment approach was based on modelling the electric field distribution (5, 6), which could be especially effective for highly irregular, large mass tumours. The images from CT were uploaded to the web-based electric field visualization tool Visifield (www.visifield.com, University of Ljubljana, Slovenia) (7). Bone of the jaw, tumour tissue, and surrounding soft tissue were segmented (Fig.3A). The total reconstructed volume of the tumour tissue was 88 cm³. Then, 7 individual needle electrodes with 4 cm exposed tips were inserted from the anterior side. Their number was chosen to provide sufficient electric field strength in the whole tumour. This provided coverage of the whole tumour mass with at least 300 V/cm electric field, and more than 98% of the tumour volume was covered with at least 400 V/cm electric field. This simulation showed that the whole tumour volume could be potentially treated in a single electrochemotherapy session and therefore eliminate the need for partial or complete surgical resection (Fig.3B). The only limitation is that no pulse generator is commercially available that allows the connection of more than 6 individual electrodes, so cables would have to be manually reconnected. The methods applied in electric field modelling and treatment plan optimization are presented in more detail in previous works (8-11).

Discussion

This case demonstrates that surgical methods can be effectively combined with ECT in palliative melanoma treatments. In the first treatment session, standard surgery and CO₂ laser surgery accompanied by ECT with bleomycin were applied. As previously reported, calcium electroporation can be highly efficient in eradicating tumours *in vivo* (13, 14) and, moreover, calcium solution is not toxic. Therefore, taking into consideration the condition of the dog, during the second treatment session we chose ECT with only calcium chloride. The treated metastatic nodules were not detectable

after one month. This may be due to a delayed response of the metastases following the first session with ECT with bleomycin, as was noted in other studies (15, 16). However, additional response of the immune system enhanced by electroporation with calcium ions could also contribute to the observed effects (13, 16, 17). We conclude that the final outcome was the result of the additive effects of laser surgery and ECTs with bleomycin and calcium. A combination approach using ECT and surgery seems to be promising in palliative melanoma treatment (18, 19), as was suggested previously for human patients.

Additionally, we show the possibility of performing pre-treatment planning using specialized software such as Visifield (www.visifield.com, University of Ljubljana, Slovenia). ECT is currently applied with standard operating procedures using predefined fixed electrode geometries (19, 20), or using individual patient treatment planning to predict the electroporation outcome related to the treatment procedure (7, 12). However, efficient ECT of large tumours with variable geometry electrodes could rely on realistic computer models to provide better results. In this way more details, including number of electrodes, electrodes positioning, and the resulting electric field distribution could be taken into consideration (21). Currently, this approach is applied only for human ECT, mainly for treatment of deep-seated tumours (7, 12, 20-22). Application of treatment planning in veterinary procedures could result in much more effective ECT.

Conclusions

We present a case of canine oral melanoma which was treated by ECT for the first time in Poland. Our observations indicate that ECT enhanced the surgical effect and stopped bleeding during the surgery. The treatment enabled normal feeding and faster recovery to physiological activities. The protocol combining ECT and surgery is promising in palliative melanoma treatment.

Acknowledgments

This work was supported partially by the grant NCS SONB.A040.17.001 (PI J.Kulbacka) and was possible due to networking efforts of COST Action TD1104 (www.electroporation.net). The work of

BK, DM and MČ was performed in the scope of LEA EBAM – European Laboratory of Pulsed Electric Fields Applications in Biology and Medicine. We thank Dr. Wayne Fisher for critical review of the manuscript.

References

1. Bergman PJ. Canine oral melanoma. *Clin Tech Small Anim Pract* 2007; 22(2): 55–60.
2. Desmas I. Canine oral melanoma. *Vet Irel J* 2013; 3(7): 398–401.
3. Bowlt K, Starkey M, Murphy S. Oral malignant melanoma in dogs. *Vet Times* 2013; 36: 27–9.
4. Cemazar M, Tamzali Y, Sersa G, et al. Electrochemotherapy in veterinary oncology. *J Vet Intern Med* 2008; 22(4): 826–31.
5. Tozon N, Kodre V, G. Sersa G, Cemazar M. Effective treatment of perianal tumors in dogs with electrochemotherapy. *Anticancer Res* 2005; 25(2A): 839–45.
6. Miklavcic D, Snoj M, Zupanic A, et al. Towards treatment planning and treatment of deep-seated solid tumors by electrochemotherapy. *Biomed Eng Online* 2010; 9: e10 (12 pp.) <https://biomedical-engineering-online.biomedcentral.com/articles/10.1186/1475-925X-9-10>
7. Edhemovic I, Brecej E, Gasljevic G, et al. Intraoperative electrochemotherapy of colorectal liver metastases. *J Surg Oncol* 2014; 110(3): 320–7.
8. Marčan M, Pavliha D, Kos B, Forjanič T, Miklavčič D. Web-based tool for visualization of electric field distribution in deep-seated body structures and planning of electroporation-based treatments. *Biomed Eng Online* 2015; 14(Suppl 3): eS4 (13 pp.) <https://biomedical-engineering-online.biomedcentral.com/articles/10.1186/1475-925X-14-S3-S4>
9. Kos B, Zupanic A, Kotnik T, Snoj M, Serša G, Miklavčič D. Robustness of treatment planning for electrochemotherapy of deep-seated tumors. *J Membr Biol* 2010; 236(1): 147–53.
10. Kos B, Voigt P, Miklavcic D, Moche M. Careful treatment planning enables safe ablation of liver tumors adjacent to major blood vessels by percutaneous irreversible electroporation (IRE). *Radiol Oncol* 2015; 49(3): 234–41.
11. Zupanic A, Kos B, Miklavcic D. Treatment planning of electroporation-based interventions: electrochemotherapy, gene electrotransfer and irreversible electroporation. *Phys Med Biol* 2012;

57(17): 5425–40.

12. Grosej A, Kos B, Cemazar M, et al. Coupling treatment planning with navigation system: a new technological approach in treatment of head and neck tumors by electrochemotherapy. *Biomed Eng Online* 2015; 14(Suppl 3): eS2 (14 pp.) <https://biomedical-engineering-online.biomedcentral.com/articles/10.1186/1475-925X-14-S3-S2>

13. Frandsen SK, Gissel H, Hojman P, Tramm T, Eriksen J, Gehl J. Direct therapeutic applications of calcium electroporation to effectively induce tumor necrosis. *Cancer Res* 2012; 72(6):1336–41.

14. Gehl KJ, Frandsen SK, Eriksen JO, Giessel HM, Hojman PJ. Therapeutic applications of calcium electroporation to effectively induce tumor necrosis. Patent No: EP2797608. Aarhus: Herlev Hospital, Aarhus Universitet, 2014.

15. Caracò C, Mozzillo N, Marone U, et al. Long-lasting response to electrochemotherapy in melanoma patients with cutaneous metastasis. *BMC Cancer* 2013; 13: e564 (4 pp.) <https://bmccancer.biomedcentral.com/articles/10.1186/1471-2407-13-564>

16. Spugnini EP, Pizzuto M, Filipponi M, et al. Electroporation enhances bleomycin efficacy in cats with periocular carcinoma and advanced squamous cell carcinoma of the head. *J Vet Intern Med* 2015; 29(5): 1368–75.

17. Frandsen SK, Gissel H, Hojman P, Eriksen J, Gehl J. Calcium electroporation in three cell lines: a comparison of bleomycin and calcium, calcium compounds, and pulsing conditions. *Biochim Biophys Acta* 2014; 1840(3): 1204–8.

18. Calve CY, Famin D, André FM, Mir LMI. Electrochemotherapy with bleomycin induces hallmarks of immunogenic cell death in murine colon cancer cells. *Oncoimmunol* 2014; 3(4): e28131 (10 pp.) <http://www.tandfonline.com/doi/abs/10.4161/onci.28131>

19. Campana LG, Bianchi G, Mocellin S, et al. Electrochemotherapy treatment of locally advanced and metastatic soft tissue sarcomas: results of a non-comparative phase II study. *World J Surg* 2014; 38(4): 813–22.

20. Campana LG, Testori A, Mozzillo N, et al. Treatment of metastatic melanoma with electrochemotherapy. *J Surg Oncol* 2014; 109(4): 301–7.

21. Miklavčič D, Serša G, Breclj E, et al. Electrochemotherapy: technological advancements for efficient electroporation-based treatment of internal tumors. *Med Biol Eng Comput* 2012; 50(12): 1213–25.

22. Pavliha D, Kos B, Zupanič A, Marčan M, Serša G, Miklavčič D. Patient-specific treatment planning of electrochemotherapy: procedure design and possible pitfalls. *Bioelectrochemistry* 2012; 87: 265–73.

ELEKTROKEMOTERAPIJA V KOMBINACIJI S STANDARDNO IN LASERSKO CO₂ KIRURGIJO PASJIH USTNIH MELANOMOV

J. Kulbacka, J. Paczuska, N. Rembiałkowska, J. Saczko, Z. Kiełbowicz, W. Kinda, B. Liszka, M. Kotulska, B. Kos, D. Miklavčič, N. Tozon, M. Čemažar

Povzetek: Oralni melanom se pogosteje pojavlja pri starejših psih, kot temno pigmentirano področje ustne sluznice, jezika in dlesni. V prispevku opisujemo primer paliativnega zdravljenja obsežnega melanoma na področju spodnje čeljusti 15-letnega psa z elektrokemoterapijo. Tumorska masa se je vraščala tudi v spodaj ležečo kost. Delno kirurško odstranitev tumorske mase s klasično in CO₂ lasersko kirurško metodo smo dopolnili z elektrokemoterapijo z bleomicinom in z raztopino kalcijevega klorida (CaCl₂). S kombinacijo terapij smo dosegli dobro lokalno kontrolo tumorja. Elektrokemoterapija neposredno po kirurškem posegu je tudi močno zmanjšala krvavitev. Pes je po posegu okrevljal hitro ob ohranitvi vseh fizioloških funkcij, vključno z normalnim hranjenjem.

Delna kirurška resekcija v kombinaciji z elektrokemoterapijo bi bila lahko alternativna možnost paliativnega zdravljenja oralnega melanoma.

Ključne besede: ustni melanom; laser CO₂; elektrokemoterapija; bleomicin; kalcijevi ioni