

## **Possibilities and limitations of cytology in the diagnosis of lung tumors**

**Milivoj Mermolja**

*Institute for Respiratory Diseases Golnik, Slovenia*

---

*The possibilities and limitations of pulmonary cytology are presented. In a two-year period, 744 primary lung carcinomas were diagnosed. In 96.5% of patients any kind of material was cytologically examined. The sensitivity of cytology was 92.0% and the predictive value of positive cytologic finding was 99.7%. The most frequently bronchoscopically obtained material (BOM), which gives the highest rate of positivity was examined. In 56.4% of patients lung cancer was microscopically verified only by cytology. In 65.7% of histologically and cytologically diagnosed lung cancers cytologically determined type agreed with the histological typing. The main advantages of pulmonary cytology could be expressed as follows: the method is minimally invasive, inexpensive, rapid, safe and reliable. Yet, in some cases the nature of the material prevents additional stainings or immunocytochemistry and therefore in nonepithelial and poorly differentiated tumors the results are less satisfactory.*

**Key words:** lung neoplasms; cytodiagnosis

---

### **Introduction**

Over the last decades the use of cytology in the diagnosis of lung cancer has gained in its frequency and importance.<sup>1</sup> In its development, pulmonary cytology is going hand in hand with technical advances, such as fiberoptic bronchoscopy and transthoracic needle aspiration biopsy (TNAB) performed under X-ray or computed tomography guidance. At the same time pulmonary cytology has also been following modern trends in material processing. Standard

cytologic staining methods such as May-Grünwald-Giemsa and Papanicolaou have been accomplished by immunocytochemistry, electron microscopy, flow cytometry and image analysis.

With the improvement of diagnostic and therapeutic regimens for the treatment of lung cancer, precise diagnoses have become very important. In the evaluation of cytology two important questions arise. First, to what extent is the method capable of detecting the presence of malignant cells, and second, to what extent it can determine the histologic type of cancer<sup>2</sup>, or at least to what extent small-cell carcinomas could be cytologically distinguished from non-small-cell lung cancers.

To establish the real possibilities and limitations of pulmonary cytology, the diagnostic

Correspondence to: Milivoj Mermolja, Ph.D., dipl. biol., Institute for Respiratory Diseases Golnik, 64204 Golnik, Slovenia.

sensitivity and tumor typing accuracy were analysed in all patients with primary lung cancer diagnosed in two-year period.

### Material and methods

In patients with primary lung cancer diagnosed during the years 1990 and 1992, the data on cytologically examined patients, materials, efficiency of examinations of different materials, sensitivity of cytology and predictive value of positive cytologic findings have been retrospectively analysed. Also the data on the efficiency, expedience and cost-effectiveness of the examination of different materials have been evaluated. The agreement between cytological and histological typing of lung cancer has been assessed as well.

Cytologically, several materials were examined: sputum, bronchoscopically obtained material (BOM), TNAB, pleural effusions and aspiration biopsies of metastatic lesions. In BOM the imprints of bronchial and transbronchial forceps biopsy specimens, brushings, perbronchial aspiration biopsies and bronchoalveolar lavage were included. Material obtained by TNAB may originate from the lungs or mediastinal lesions.

In BOM the cytological examination is performed first. If cytology of imprints is positive and the type of carcinoma is clearly determined, the histology of forceps biopsy specimens is usually not performed. The exceptions are small cell lung cancers which are in most cases histologically verified as well.

Most of the cytological smears are stained by the May-Grünwald-Giemsa method. If the material is appropriate, some smears are stained according to Papanicolaou. If cancer cannot be typed on the basis of cell morphology, the smears stained by Papanicolaou are used for appropriate immunocytochemical staining.

The results of cytology were recorded as positive, suspicious or negative. The type of primary lung cancer was in most cases determined on the basis of the morphology of malignant cells. In patients with both cytologically and

histologically verified lung cancer, the accuracy of cytologic typing was compared with histologically established diagnosis. The results of cytological typing were classified into three groups: 1) both typings were in agreement, 2) typings were only partly in agreement, 3) typings were not in agreement. In the first group those cases were included in which the type was cytologically clearly defined and was in agreement with histologically determined type.

The second group comprised the cases in which the type had not been definitively cytologically determined. For example, we noted that the cells probably belonged either to squamous cell carcinoma, small-cell or adenocarcinoma. In this group also those cases were included which had been cytologically classified as large-cell carcinoma, while histologically they were classified as squamous cell carcinoma or adenocarcinoma.

In the third group there were the cases in which the type was cytologically definitively determined however, later histology proved the diagnosis to be incorrect.

### Results

In the years 1990 and 1992, 744 primary pulmonary carcinomas were diagnosed at our Institute. Any type of material was cytologically examined in 96.5% of patients. Cytological findings were positive in 661 patients (Table 1). In two patients cytological findings were false positive. From these data it was concluded that the sensitivity of cytological examination was 92.0% and the predictive value of positive cytologic finding was 99.7%.

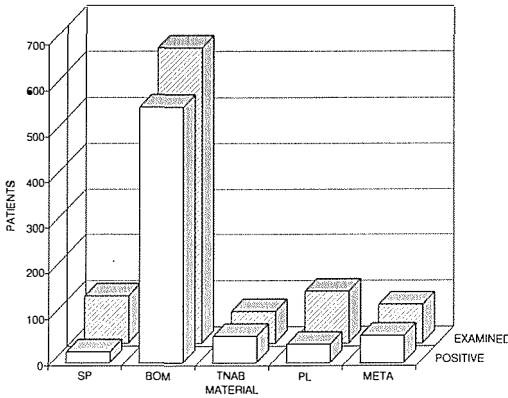
**Table 1.** Cytology in patients with lung cancer: examinations and results.

Patients	N
Without cytology	26
Cytologically examined	718
– positive	661
– suspicious	18
– negative	39
All patients	744

BOM was examined in most patients with lung cancer. The examination of this material yielded the highest rate of positivity (86.6%) (Figure 1). TNAB was examined in 9.3% of

found in six patients only while in BOM and TNAB they were found in seven patients only.

In more than half of the patients the cancer was microscopically verified by cytology only (Figure 2). In nearly one third of cases cancer was verified both histologically and cytologically, while in 2.4% it was confirmed only histologically. In 9.7% of the patients cancer was not microscopically verified. Also, in most of the surgically treated patients, lung cancer was preoperatively microscopically verified only by cytology (Table 2).



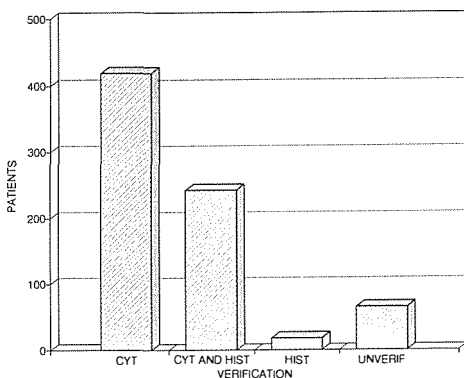
**Figure 1.** Frequency and efficiency of cytology of several materials. SP = sputum; BOM = bronchoscopically obtained material; TNAB = transthoracic needle aspiration biopsy; PL = pleural effusion; META = metastatic lesions.

patients, its sensitivity being 82.6%. Rather poor positive results were obtained by the examination of sputum (22.5%) and pleural effusions (34.8%).

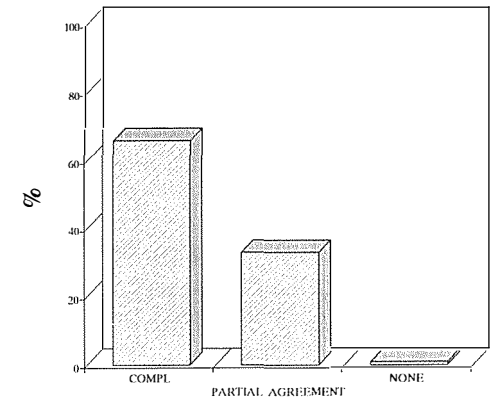
In most patients malignant cells were found only in one type of material. For example, in both BOM and sputum malignant cells were

**Table 2.** Microscopic verification of lung cancer before surgery.

Verification	N
Cytology only	93
Cytology and histology	17
Histology only	3
Unverified	2
All patients	115



**Figure 2.** Microscopic verification of lung cancer. N = 774. CYT = only cytologically verified; CYT and HIST = cytologically and histologically verified; HIST – only histologically verified; UNVERIF = without microscopic verification.



**Figure 3.** Agreement of cytological and histological typing. N = 242. COMPL = both typings are in full agreement; PARTLY = both typings are in partial agreement; NONE = histological and cytological typings are in disagreement.

The efficiency of cytological typing was assessed in 242 patients (Figure 3) in whom cancer was verified both cytologically and histologically. In 65.7% of cases the cytologic and histologic typings were in full agreement, in 33.1% of cases the typings were only in partial agreement, while in 1.2% of patients the cytological typing of carcinoma was incorrect.

**Table 3.** Agreement of cytological typing with histology in different types of lung cancer.

Type	Number of patients	Correctly typed	
		N	%
Squamous	52	37	71.2
Small cell anaplastic	91	70	76.9
Adenocarcinoma	51	24	47.1
Large cell	32	19	59.4
All patients	226	150	66.4

Cytological typing was most successful in small-cell lung cancer where cytologically determined type was in agreement with histologically determined type in 76.9% of cases, and in squamous cell carcinoma where the typings were in agreement in 71.2% of cases. Less successful was cytological typing in adenocarcinoma and large cell carcinoma where the typings were in agreement only in 47.1% and 59.4% of cases, respectively (Table 3).

### Discussion

Among the methods available for the diagnostics of lung cancer, cytology plays a very important role. Different materials for cytological examinations are available. However, each type of material has some advantages as well as drawbacks. For example, the examinations of sputum yield the diagnostic sensitivity of 85% or more when three or more sufficient samples are examined.<sup>3</sup> However, the examinations of sputum are rather time-consuming; besides, positive sputum cytology does not provide information on the extent and localisation of tumor. Therefore, in the past years sputum is examined only in patients in whom for various reasons a more aggressive method of sample taking is not indicated.

Recently, examinations of BOM have been performed in most patients suspected of having lung cancer. Since the sensitivity of BOM cytology is high, most lung cancers are proven by this examination. By bronchoscopy, different kinds of material for cytology may be obtained. The diagnostic sensitivity of different types of BOM was not analysed in our material. Better results are usually obtained by the examination

of imprints than by brushings. The results of imprint cytology are also better than those of histological examination of forceps biopsy specimens.<sup>4</sup> The sensitivity of BOM cytology is higher in central than in periphery tumors.<sup>5</sup>

TNAB is generally indicated for the diagnosis of nodules, masses or infiltrates that are not accessible by a bronchoscope. It provides a quick and accurate diagnosis. If performed in an early phase of diagnostic workup, it can save many other laboratory tests and examinations.<sup>6</sup> It is also a reliable method for reducing the need for diagnostic thoracotomy.<sup>7</sup> At our Institute it is performed in 9.3% of patients with lung cancer. The diagnostic sensitivity of these examinations is usually high.<sup>8</sup> In most cases the examinations are more efficient in pulmonary than in mediastinal lesions.<sup>9</sup> In the mediastinum tumors of nonepithelial origin are rather frequent and their identification requires additional immunochemical stainings.

Malignant pleural effusion is a sign of inoperability of lung cancer. So the cytology of pleural effusion is important not only for the diagnosis but also for the staging of disease. However, the cytology of pleural effusion is complicated since in many cases, even in patients with lung cancer, the effusion is not due to a direct pleural involvement<sup>10</sup> but may also be caused by a lymphatic or venous obstruction, endobronchial obstruction with atelectasis, postobstructive pneumonitis and severe hypoproteinemia.<sup>11</sup> In cases where the pleura is not involved, malignant cells will not be found in the effusion. Even if there are few malignant cells in the effusion or effusion is very hemorrhagic, malignant cells may not be present in the examined sample. Therefore it is difficult to establish the real diagnostic sensitivity of cytology of pleural effusion. Direct involvement of the pleura might be established only on autopsy, thoracotomy or thoracoscopy, but these are performed in a rather small number of patients with pleural effusion.

However, in cytological examinations it is not enough to find malignant cells only. The type of primary lung cancer should also be determined or at least small-cell carcinomas

should be differentiated from non-small-cell carcinomas. Undoubtedly, the histological typing is more reliable than the cytological one. Yet, many a sample from the lung is suitable for cytologic examination only. In routine, cytological examinations are quick and inexpensive. Therefore, at our Institute in more than half of the patients with lung cancer the preoperative microscopic diagnosis and typing of tumor are based on cytological finding only (Figure 2).

The reliability of cytological typing may be improved if immunochemistry is applied in addition to standard stainings. Yet, some cytological samples do not contain enough material or it is of poor quality for additional stainings. Therefore, cytologic diagnostics and typing are based mostly on the examination of routinely stained smears. Yet, in 65.7% of cases with cytologically and histologically verified lung cancer, the cytological typing was in full agreement with the histological type. Cytological typing was most efficient in small-cell and squamous-cell lung cancer. In prospective studies including a small number of patients, the results of cytological typing may be better<sup>12, 13</sup> than those indicated in our review.

Yet, it should be considered that our criteria were very strict. Those cases in whom the type had not been cytologically clearly defined were included into a separate group. It is known that cytological typing is less reliable in poorly differentiated non-small-cell lung cancers which are mostly typed as large-cell carcinomas or adenocarcinomas. It is also evident that cytologically, non-small-cell lung cancers are hardly ever falsely typed as small-cell cancers or vice versa.

According to our data it can be concluded that the basic advantages of pulmonary cytology are as follows: sample taking is relatively well tolerated by patients, the method is quick and cost effective, the yield of diagnostic sensitivity can reach up to 90% or even more, the rate of false positive results is under 1% and the accuracy of tumor typing exceeds 60%.

As to the disadvantages of pulmonary cytology, it should be mentioned that for good diagnostic results several materials should be examined. If the material was sputum, examina-

tions should be repeated. The nature of the material often renders additional stainings impossible therefore particularly in nonepithelial and poorly differentiated tumors the results are not as good as it might be desired.

## References

1. Johnston WW. Cytologic diagnosis of lung cancer. Principles and problems. *Path Res Pract* 1986; **181**: 1-36.
2. Erozan YS. Cytopathology in pulmonary biopsy procedures. In: Ko Pen Wang ed. *Biopsy techniques in pulmonary disorders*. New York: Raven Press Ltd., 1989: 139-57.
3. Bocking A, Biesterfeld S, Chatelain R, Gien-Gerlach G, Esser E. Diagnosis of bronchial carcinoma on sections of paraffin embedded sputum. *Acta Cytol* 1992; **36**: 37-47.
4. Popp W, Rauscher H, Ritschka L, Redtenbacher S, Zwick H, Dutz W. Diagnostic sensitivity of different techniques in the diagnosis of lung tumors with the flexible fiberoptic bronchoscope. *Cancer* 1991; **67**: 72-5.
5. Mak VHF, Johnston IDA, Hetzel MR, Grubb C. Value of washings and brushings at fiberoptic bronchoscopy in the diagnosis of lung cancer. *Thorax* 1990; **45**: 373-6.
6. Weisbrod GL. Transthoracic needle biopsy. *World J Surg* 1993; **17**: 705-11.
7. Cristallini EG, Ascani S, Farabi R, Paganelli C, Peciarolo A, Bolis GB. Fine needle biopsy in the diagnosis of intrathoracic masses. *Acta Cytol* 1992; **36**: 416-22.
8. Zarbo RJ, Fenoglio-Preiser CM. Interinstitutional database for comparison of performance in lung fine-needle aspiration cytology. *Arch Pathol Lab Med* 1992; **116**: 463-70.
9. De Gregorio Ariza MA, Aguiran ERA, Atance JLV, et al. Transthoracic aspiration biopsy of pulmonary and mediastinal lesions. *Eur J Radiol* 1991; **12**: 98-103.
10. Sahn SA. Malignant pleural effusions. *Clin Chest Med* 1985; **6**: 113-25.
11. Irani DR, Underwood RD, Johnson EH, Greenberg SD. Malignant pleural effusions. A clinical cytopathologic study. *Arch Intern Med* 1987; **147**: 1133-6.
12. Barbazza R, Toniolo L, Pinarello A, Scapinello A, Falconieri G, Di Bonito L. Accuracy of bronchial aspiration cytology in typing operable (stage I-II) pulmonary carcinomas. *Diagn Cytopathol* 1992; **8**: 3-7.
13. Di Bonito L, Colautti I, Patriarca S, Falconieri G, Barbazza R, Vielh P. Cytological typing of primary lung cancer: Study of 100 cases with autopsy confirmation. *Diagn Cytopathol* 1991; **7**: 7-10.