

# The diffuse palmoplantar keratodermas

S. J. Hatsell and D. P. Kelsell

---

## SUMMARY

Diffuse palmoplantar keratodermas belong to a diverse group of skin disorders affecting the palms and soles. These keratodermas manifest as a diffuse thickening of the palmoplantar skin, which can often be associated with other ectodermal disorders. Classification within this group has often been difficult due to the overlapping of phenotypes between disorders and the diversity within one particular disease. During the last few years advances in the molecular characterization of many of the keratodermas has helped both in distinguishing the different diseases and increasing our understanding of skin biology.

---

## Introduction

Hereditary palmoplantar keratodermas (PPKs) are a highly heterogeneous group of skin diseases, which primarily affect the palms, and soles or palmoplantar skin and involve thickening and hyperkeratosis. They can be inherited in both an autosomal dominant and recessive fashion. PPKs can be divided into three subgroups according to their phenotype. *Simple keratodermas* manifest as lesions only on the palmoplantar skin, whereas *complex keratodermas* are associated with lesions of non-volar skin, hair, teeth, nails or sweat glands. *Syndromic keratodermas* are associated with abnormalities of other organs such as deafness, cancer, cardiomyopathy, and adrenal insufficiency.

*Simple keratodermas* can be divided, by the clinical pattern of keratoderma, into three main groups, the diffuse, focal and punctate PPK. *Syndromic forms* of

keratoderma are normally associated with either a diffuse or focal pattern of keratoderma, with secondary disorders including deafness and cardiomyopathy. As the name suggests, in diffuse PPK the pattern of keratoderma is uniform across the palmoplantar skin. This compares with focal PPK, in which the keratoderma develops at pressure points or sites of trauma and punctate keratoderma, which results in numerous small hyperkeratotic nodules.

Classification of the diffuse PPKs when relying on clinical findings can be ambiguous, due to the overlap of certain clinical features between disorders and heterogeneity within the same disorder. The heterogeneity seen in phenotype throughout the diffuse PPKs is partly reflected in the diversity of genetic mutations discovered to date. However in many PPKs there can be considerable variation in phenotype between families and within families with the same genetic defect. Mutations

## KEY WORDS

palmoplantar, keratoderma, hereditary, diffuse, molecular biology

so far have been found in *structural, adhesion and gap junctions proteins* (Figure 1), though there are other loci associated with PPK for which the specific gene defects have yet to be identified. In this review, we discuss a classification and the current molecular understanding of the diffuse PPKs.

## Simple diffuse PPK

Two different forms of the simple PPK showing a diffuse pattern of lesion have been described, diffuse epidermolytic PPK (EPPK) and diffuse non-epidermolytic PPK (NEPPK).

EPPK also known as Vörner's disease, first described in 1901 and diffuse NEPPK also called Unna-Thost type, after the clinicians who first reported it, are often phenotypically confused (1-3). Both are present from infancy and are characterized by hyperkeratosis covering the entire palms and soles. EPPK tends to have thick fissured pattern, which is bordered with erythematous margins; compared with NEPPK (Figure 2a) which usually has a more yellow waxy appearance though the phenotype in both diseases can vary greatly even within a family. The lesions on the skin in NEPPK are often susceptible to secondary dermatophyte infection and hyperhidrosis is common. Spreading onto the dorsal surfaces of the hands and wrists with a sharp cut off is a feature of NEPPK, though knuckles pads can be present in EPPK. Nail changes may be observed in both disorders. Both diseases are inherited in an autosomal dominant fashion and are highly penetrant.

Histologically the two diseases can be easier to distinguish, with EPPK showing keratin filament clumping in the suprabasal cells of the epidermis. Perinuclear vacuolization of keratinocytes and large irregularly shaped keratohyalin granules in the granular layer are also a feature of EPPK not seen in NEPPK. NEPPK can be identified by the presence of orthokeratotic hyperkeratosis and epidermal hyperplasia.

Both disorders are linked to regions of the genome containing a keratin gene cluster, with EPPK linked to 17q12-21 harboring the type I keratin gene cluster (4) and NEPPK to 12q13 where the type II keratin gene cluster maps (5, 6). Keratins are a large family of structural proteins and are the major components of the cytoskeleton of keratinocytes. These intermediate filament proteins fall into two groups, the type I and type II keratins which form specific heterodimers and are expressed in a tissue and differentiation specific pattern (7). Many different epidermal diseases have been attributed to keratin mutations, which are proposed to disrupt the cytoskeleton of the cell leading to collapse of the cell and loss of adhesion (8).

The most likely candidate for EPPK was the type I

keratin, keratin 9, as the expression of this protein is restricted to the suprabasal keratinocytes in palmoplantar epidermis (9). Subsequently mutations have been found in keratin 9 in patients with EPPK (10), and have so far been shown to be a homogeneous disease with keratin 9 mutations being found in the majority of patients investigated (11-16). Most lie in the mutation hotspot region situated in the helix initiation motif in the 1A domain. This is a highly conserved protein domain both in keratin genes and other intermediate filaments and is involved in the dimerisation of intermediate filaments. The most common mutations have been shown to change the same residue that is altered in keratin 14 in epidermolysis bullosa simplex and keratin 10 in epidermolytic hyperkeratosis respectively (17, 18).

Families with NEPPK from both the UK and Northern Sweden have both been linked to 12q13. Sequence analysis of the UK and Swedish families excluded the type II suprabasal keratin 1 and keratin 6 which are present in palmoplantar epidermis. Further mapping studies using more families has placed the disease locus proximal to the keratin cluster suggesting that a keratin is not responsible for the British and Northern Swedish form of NEPPK (19). Further studies to identify the gene is in progress, genes localized in this region include elastase 1 which has been excluded from this disease (20).

A keratin 1 mutation has been found in a family with NEPPK (21). This family however showed more epidermal involvement with hyperkeratosis of the navel and areolae not seen in other families with NEPPK. This phenotypic difference is probably a consequence of the generalized expression of keratin 1 throughout the epidermis of all body sites with affected sites being those which may be subject to greater physical stress.

## Complex diffuse PPK

### *Erythrokeratoderma Variabilis*

*Erythrokeratoderma variabilis* (EKV) is a phenotypically variable disease and was first described in 1925 (22). It is an autosomal dominant disease, which presents either at birth or within the first year as diffuse thickening of the palmoplantar epidermis with persistent generalized pigmented rough hyperkeratosis (fig. 2c). Patients also suffer from symmetrically distributed fixed hyperkeratotic plaques, which are sharply demarcated and can persist for months or years. Transient erythematous areas occur independently to the hyperkeratosis, lasting from minutes to days, and are usually preceded by a burning sensation (fig. 2d). Both the hyperkeratosis and erythematous patches can be triggered by trauma

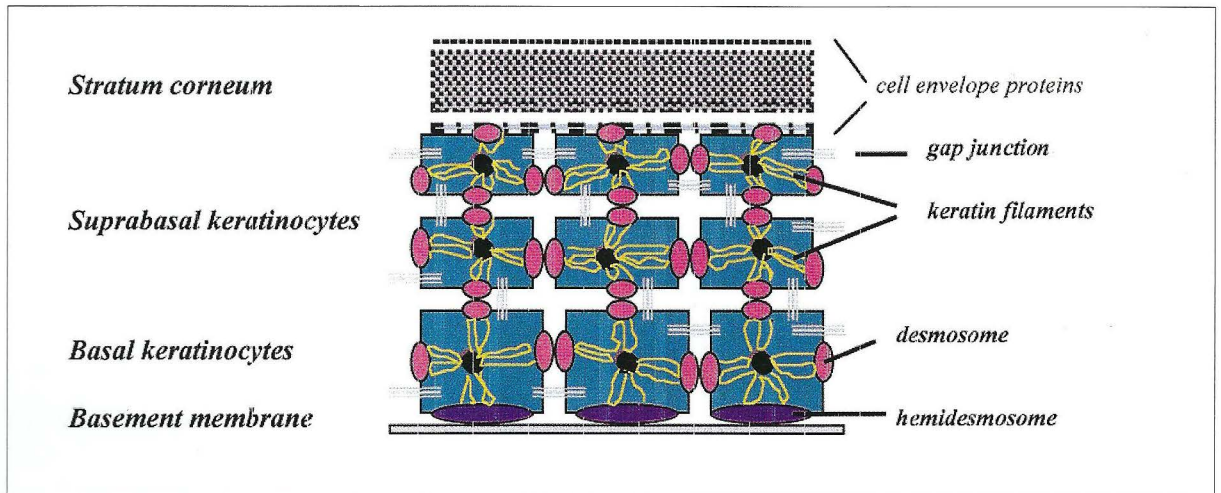


Figure 1. (a) Diagram showing the components of palmoplantar epidermis associated with diffuse palmoplantar keratodermas (PPK).

to the skin, temperature changes, UV exposure, and emotional stress. The lesions affect the whole body but are more often found on the face, buttocks and extensor surfaces of the limbs. Histologically EKV shows no specific features, but there is generalized hyperkeratosis, acanthosis, papillomatosis, dilated capillaries and perivascular infiltration. With increasing age the areas of the body affected by EKV become more restricted to the palmoplantar epidermis.

In a number of families with EKV, the disease has been linked to 1p34-p36 (23) and subsequently mutations have been found in the gap junction  $\beta$ -3 gene (GJB3) which encodes connexin 31 (24, 25). Four mutations causing EKV have been identified so far in the intercellular, extracellular and transmembrane domains of connexin 31. Gap junctions are composed of co-

nexin proteins, a diverse group of proteins expressed in a tissue and differentiation specific manner of which 13 human forms have been described so far. These connexins oligomerise to form connexons which are situated in the plasma membrane and colocalise homotypically or heterotypically with connexons on adjacent cells to form a direct inter-cytoplasmic channels (fig. 1b). These channels play an important role in cell-cell communication by regulation of the transport of small molecules, such as signaling molecules and metabolites between cells. This communication is likely to control a wide range of cellular activities such as growth and differentiation.

A disease phenotypically similar to EKV, progressive symmetric erythrokeratoderma (PSEK), has been described in a Japanese family. Overlapping phenotypic

Figure 1. (b) Electron microscopy showing structure of desmosomes and gap junctions.

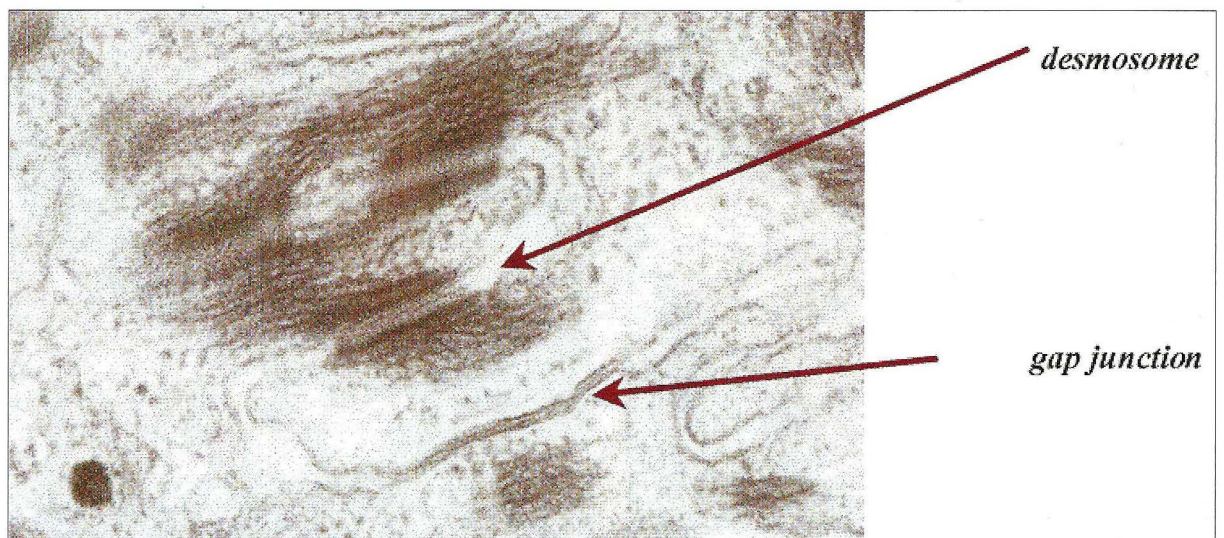

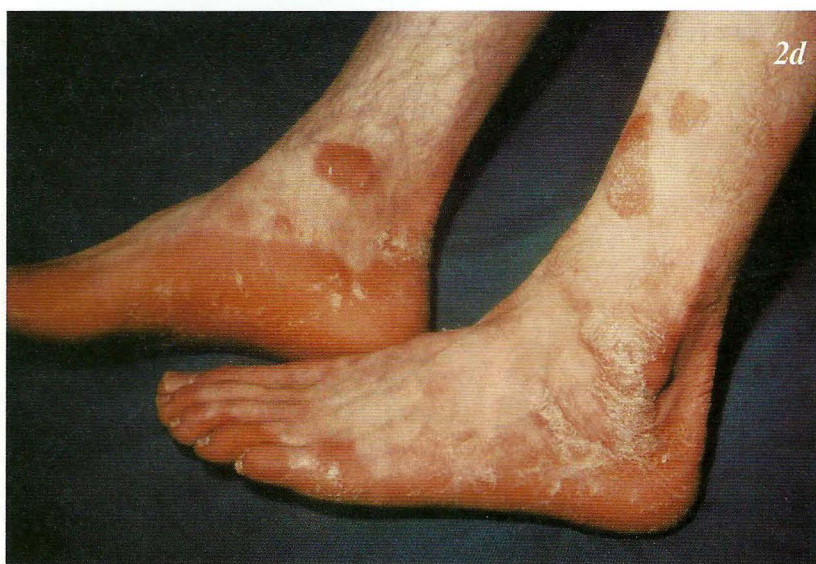
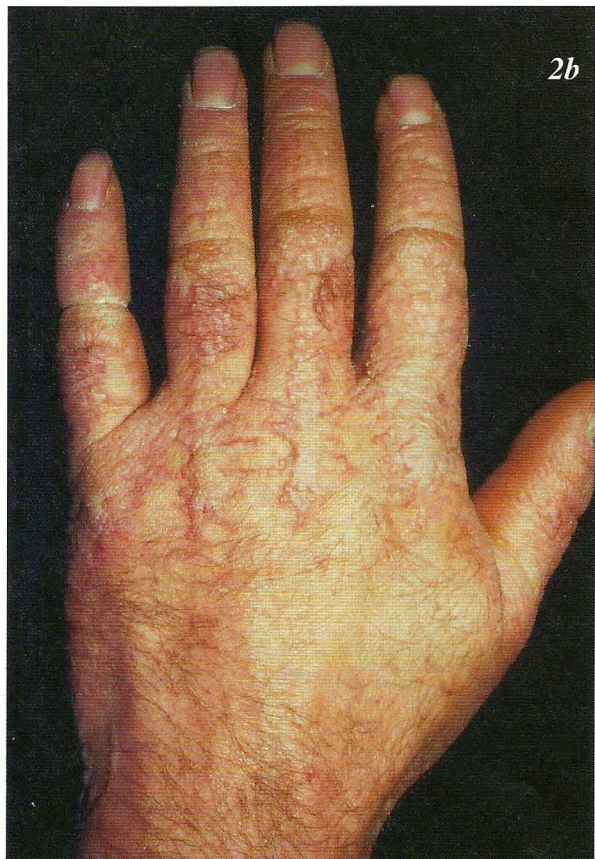
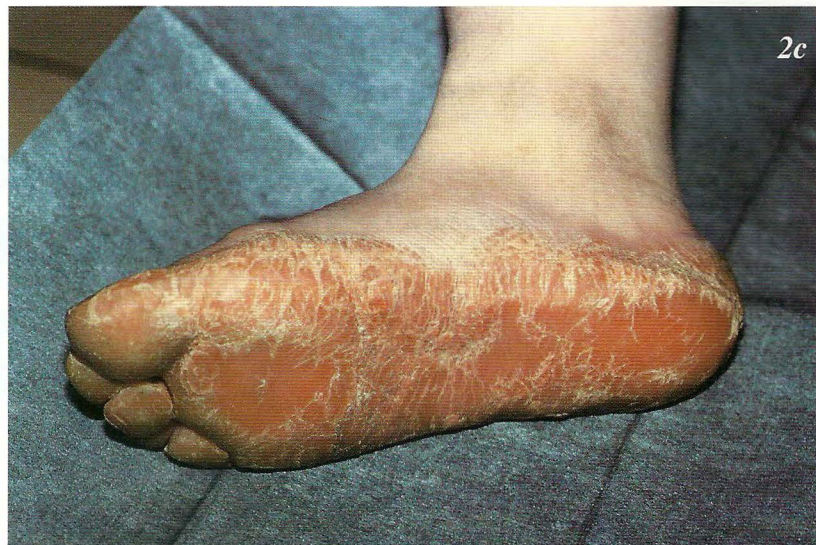
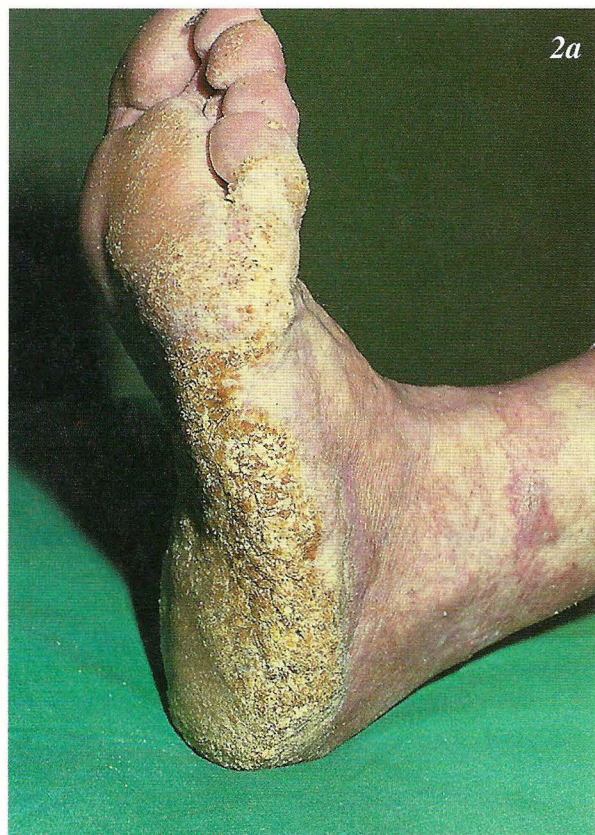Figure 2. Photographs showing the different phenotypes of diffuse palmoplantar keratodermas (PPKs): (a) hyperkeratosis of the sole in non-epidermolytic palmoplantar keratoderma (NEPPK); (b) Pseudo-ainhum on the fingers in Vohwinkel's syndrome; (c) and (d) erythrodermia variabilis (EKV) with palmoplantar hyperkeratosis and erythematous keratotic patches.

characteristics with EKV include diffuse palmoplantar keratoderma and erythematous plaques mainly on the buttocks and limb extremities though facial involvement is also common. EKV, however, shows more variable erythroderma compared to PSEK. Genetically these two disorders are distinct, with a mutation in *loricrin* being identified in the family with PSEK (26). *Loricrin* is a structural gene thought to be important in cross-linking in cornified envelope formation during cornification of the epidermis.

### *Hidrotic Ectodermal Dysplasia*

An autosomal recessive type of *hidrotic ectodermal dysplasia (HED)* characterized by diffuse PPK, blistering, hyperkeratotic plaques on the limbs, sweating abnormalities and sparse hair is caused by mutations in *plakophilin 1*, a desmosomal plaque protein (27, 28). Desmosomes are responsible for adhesion between cells in most epithelia and are made up of many different proteins. The intracellular portion of the desmosome in the epidermis attaches to the keratin network of the cell maintaining cellular integrity (Figure 1b). The mutation in recessive HED causes a reduction both in the number and the size of desmosomes throughout the epidermis, which is most pronounced in the suprabasal layers. This results in a loss of adhesion between keratinocytes and consequently, histologically there are intercellular spaces in the suprabasal layers of the epidermis. Keratin networks in the cells were also disrupted presumably due to the loss of adhesion to the desmosomes.

Mutations in other desmosomal associated proteins have been linked with forms of PPK other than diffuse PPK such as desmoplakin and desmoglein 1 involvement in striate PPK, a form of focal PPK (29, 30). Striate PPK differs from diffuse PPK in the pattern of the lesions; individuals with the striate form show linear hyperkeratosis down the centre of each digit leading to the palm and hyperkeratosis on pressure points on the soles. Desmoplakin, the most common of the desmosomal proteins, is critical for the linking of keratin filaments to the plasma membrane. This disease shows widening of the intercellular spaces and an abnormal keratin filament network due to the disruption of the desmosomes and keratin filament interaction at the desmosomes.

### *Mal de Meleda*

*Meleda disease (Mal de Meleda)* shows transgressive palmoplantar keratoderma that occurs shortly after birth. This starts with redness on the palms and soles shortly followed by scaling and thickening which then spreads to the dorsal surfaces of the hands and feet and to other body parts, the knees and elbows and other sites of traumatic stress are particularly affected. Hyperhidrosis and perioral erythema are other features associated with

Mal de Meleda. This PPK is autosomal recessive and has been identified in a number of consanguineous families, in which linkage analysis has placed the gene at 8qter (31).

## *Syndromic diffuse PPK*

### *PPK and deafness*

*Vohwinkel's syndrome* also known as keratoderma hereditaria mutilans, first described in 1929 (32) is a rare autosomal dominant disorder, which manifests as hyperkeratosis of the palms and soles with a honeycomb appearance. Patients also suffer from constrictions of the skin around the digits (pseudo-ainhum), which can lead to autoamputation due to impairment of circulation and deformity of the underlying bone (Figure 2b). Also seen in these patients are starfish shaped hyperkeratotic lesions on the dorsal surface of the hands. The histopathological definition of Vohwinkel's syndrome is a thickened stratum corneum, hypergranulosis and particularly hyperkeratosis with round nuclei retained in the stratum corneum. There is overlap of the clinical features of Vohwinkel's syndrome and other disorders, for example, pseudo-ainhum have been seen in both discoid lupus erythematosus and Mal de Meleda (33, 34).

Vohwinkel's syndrome can be associated with a mild to moderate hearing loss and has been mapped to the chromosome region 13q11-q12. The phenotype is due to abnormal gap junctions caused by the mutation D66H in the gene *GJB2* encoding connexin 26 (35, 36). This mutation has been found in a number of unrelated Spanish, British and Italian families. Connexin 26 mutations, both dominant and recessive, have also been attributed to non-syndromic sensorineural deafness (37). Mutations in connexin 31 associated with EKV do not result in any type of deafness. Other dominant and recessive mutations in connexin 31 however can cause autosomal dominant non-syndromic hearing loss with no epidermal involvement (38). It is not understood why some mutations cause epidermal disorders and other hearing impairments, but it suggests that different domains of connexins are important in different cell types.

A structural protein as well as a gap junction protein defect can result in another form of Vohwinkel's syndrome. This molecular variation of the disease shows the characteristic mutilating keratoderma but also presents generalized ichthyosis and lacks hearing abnormalities. This form was linked to the epidermal differentiation complex on 1q21 and a frameshift mutation in the *loricrin* gene has been identified in a family originating in the UK (39) and in patients from Japan (40). The mutation causes *loricrin* to be abnormally or less

efficiently incorporated into the cornified envelope, due to impairment of the crosslinking of the protein by transglutaminase.

### *HED and deafness*

*Clouston's hidrotic ectodermal dysplasia* has been mapped to the same region as the classical form of Vohwinkel's syndrome, 13q11-q12 (41). This autosomal dominant disorder is characterized by palmoplantar hyperkeratosis, hyperpigmentation of the skin especially over the joints, nail dystrophy and hair abnormalities ranging from brittleness to complete alopecia. Other features associated with Clouston's HED have also been described, such as sensorineural deafness and mental retardation. This region of the genome contains a cluster of connexin genes, which are possible candidates for this disorder.

### *PPK and cardiomyopathy*

A syndromic form of NEPPK, *Naxos disease*, which originated on the Greek island of Naxos, presents as diffuse NEPPK, arrhythmogenic right ventricular cardiomyopathy and woolly hair (42). This disease is linked to 17q21 (43). Immunohistochemistry for plakoglobin, which maps to this region, reveals an abnormal distribution of the protein in affected patient skin, suggesting involvement of this gene in the disease (Hatsell and Kelsell, personal observation).

## *Discussion*

There has recently been an increase in the understanding of the molecular basis of the diffuse palmoplantar keratodermas. However, confusion still remains with regard to their clinical diagnosis due to the heterogeneity seen in the phenotype. Diagnosis may become much easier when the molecular basis of the different PPKs is known. This understanding of a subset of skin diseases will help in the overall understanding of skin biology, by providing insights into the structure and function of the cytoskeleton, desmosomes and gap junctions. Also, due to the associated involvement of other tissues in syndromic PPKs, identifying and characterizing the genetic abnormality will increase our knowledge of other organs such as the ear and the heart. For example, investigation into PPK with deafness leads to the discovery of connexin 26 as the most common cause of genetic deafness. Also with association of other forms of PPK with diseases such as esophageal cancer and neuropathy, a wide spectrum of disorders are being investigated.

### *Acknowledgements*

*We would like to thank Dr. Colin Munro for supplying clinical photographs, and to Professor Irene Leigh for discussion and reading of the manuscript.*

## REFERENCES

1. Thost A. Ueber erbliche Ichthyosis palmaris et plantaris cornea. Dissertation: Heidelberg (pub.) 1880.
2. Unna P. Ueber das Keratoma palmare et plantare hereditarium. Arch Derm Syph 1883; 15: 231-70.
3. Vorner H. Zur Kenntniss des Keratoma hereditarium palmare et plantare. Arch Derm Syph 1901; 56: 3-31.
4. Reis A, Kuster W, Eckardt R, Sperling K. Mapping of a gene for epidermolytic palmoplantar keratoderma to the region of the acidic keratin gene cluster at 17q12-q21. Hum Genet 1992; 90(1-2): 113-6.
5. Lind L, Lundstrom A, Hofer PA, Holmgren G. The gene for diffuse palmoplantar keratoderma of the type found in northern Sweden is localized to chromosome 12q11-q13. Hum Mol Genet 1994; 3(10): 1789-93.
6. Kelsell DP, Stevens HP, Ratnavel R, Bryant SP, Bishop DT, Leigh IM, et al. Genetic linkage studies in non-epidermolytic palmoplantar keratoderma: evidence for heterogeneity. Hum Mol Genet 1995; 4(6): 1021-5.
7. Moll R, Franke WW, Schiller DL, Geiger B, Krepler R. The catalog of human cytokeratins: patterns of expression in normal epithelia, tumors and cultured cells. Cell 1982; 31(1): 11-24.
8. Gorden LD, McLean WH. Human keratin diseases: hereditary fragility of specific epithelial tissues. Exp Dermatol 1996; 5(6):2 97-307.
9. Knapp AC, Franke WW, Heid H, Hatzfeld M, Jorcano JL, Moll R. Cytokeratin No. 9, an epidermal type I keratin characteristic of a special program of keratinocyte differentiation displaying body site specificity. J Cell Biol 1986; 103(2): 657-67.
10. Reis A, Hennies HC, Langbein L, Digweed M, Mischke D, Drechsler M, et al. Keratin 9 gene mutations in epidermolytic palmoplantar keratoderma (EPPK). Nat Genet 1994; 6(2): 174-9.

11. Bonifas JM, Matsumura K, Chen MA, Berth-Jones J, Hutchison PE, Zloczower M, et al. Mutations of keratin 9 in two families with palmoplantar epidermolytic hyperkeratosis. *J Invest Dermatol* 1994; 103(4):474-7.
12. Hennies HC, Zehender D, Kunze J, Kuster W, Reis A. Keratin 9 gene mutational heterogeneity in patients with epidermolytic palmoplantar keratoderma. *Hum Genet* 1994; 93(6): 649-54.
13. Torchard D, Blanchet-Bardon C, Serova O, Langbein L, Narod S, Janin N, et al. Epidermolytic palmoplantar keratoderma cosegregates with a keratin 9 mutation in a pedigree with breast and ovarian cancer. *Nat Genet* 1994; 6(1): 106-10.
14. Endo H, Hatamochi A, Shinkai H. A novel mutation of a leucine residue in coil 1A of keratin 9 in epidermolytic palmoplantar keratoderma. *J Invest Dermatol* 1997; 109(1): 113-5.
15. Covello SP, Irvine AD, McKenna KE, Munro CS, Nevin NC, Smith FJ, et al. Mutations in keratin K9 in kindreds with epidermolytic palmoplantar keratoderma and epidemiology in Northern Ireland. *J Invest Dermatol* 1998; 111(6): 1207-9.
16. Yang JM, Lee S, Kang HJ, Lee JH, Yeo UC, Son IY, et al. Mutations in the 1A rod domain segment of the keratin 9 gene in epidermolytic palmoplantar keratoderma. *Acta Derm Venereol* 1998; 78(6): 412-6.
17. Coulombe PA, Hutton ME, Letai A, Hebert A, Paller AS, Fuchs E. Point mutations in human keratin 14 genes of epidermolysis bullosa simplex patients: genetic and functional analyses. *Cell* 1991; 66(6): 1301-11.
18. Cheng J, Syder AJ, Yu QC, Letai A, Paller AS, Fuchs E. The genetic basis of epidermolytic hyperkeratosis: a disorder of differentiation-specific epidermal keratin genes. *Cell* 1992; 70(5): 811-9.
19. Kelsell DP, Stevens HP, Purkis PE, Talas U, Rustin MH, Leigh IM. Fine genetic mapping of diffuse non-epidermolytic palmoplantar keratoderma to chromosome 12q11-q13: exclusion of the mapped type II keratins. In Process Citation. *Exp Dermatol* 1999; 8(5): 388-91.
20. Talas U, Dunlop J, Khalaf S, Leigh IM, Kelsell DP. Human elastase 1: evidence for expression in the skin and the identification of a frequent frameshift polymorphism [In Process Citation]. *J Invest Dermatol* 2000; 114(1): 165-70.
21. Kimonis V, DiGiovanna JJ, Yang JM, Doyle SZ, Bale SJ, Compton JG. A mutation in the V1 end domain of keratin 1 in non-epidermolytic palmar-plantar keratoderma. *J Invest Dermatol* 1994; 103(6):764-9.
22. Mendes da Costa S. Erythro- et keratoderma variabilis in a mother and a daughter. *Acta Derm. Venerol.* 6: 255-261, 1925 1925; 6: 255-261.
23. Richard G, Lin JP, Smith L, Whyte YM, Itin P, Wollina U, et al. Linkage studies in erythrokeratodermias: fine mapping, genetic heterogeneity and analysis of candidate genes. *J Invest Dermatol* 1997; 109(5): 666-71.
24. Richard G, Smith LE, Bailey RA, Itin P, Hohl D, Epstein EH, Jr., et al. Mutations in the human connexin gene GJB3 cause erythrokeratoderma variabilis [see comments]. *Nat Genet* 1998; 20(4): 366-9.
25. Wilgoss A, Leigh IM, Barnes MR, Dopping-Hepenstal P, Eady RA, Walter JM, et al. Identification of a novel mutation R42P in the gap junction protein beta-3 associated with autosomal dominant erythrokeratoderma variabilis. *J Invest Dermatol* 1999; 113(6): 1119-22.
26. Ishida-Yamamoto A, McGrath JA, Lam H, Iizuka H, Friedman RA, Christiano AM. The molecular pathology of progressive symmetric erythrokeratoderma: a frameshift mutation in the loricrin gene and perturbations in the cornified cell envelope. *Am J Hum Genet* 1997; 61(3): 581-9.
27. McGrath JA, McMillan JR, Shemanko CS, Runswick SK, Leigh IM, Lane EB, et al. Mutations in the plakophilin 1 gene result in ectodermal dysplasia/skin fragility syndrome. *Nat Genet* 1997; 17(2): 240-4.
28. McGrath JA, Hoeger PH, Christiano AM, McMillan JR, Mellerio JE, Ashton GH, et al. Skin fragility and hypohidrotic ectodermal dysplasia resulting from ablation of plakophilin 1. *Br J Dermatol* 1999; 140(2): 297-307.
29. Rickman L, Simrak D, Stevens HP, Hunt DM, King IA, Bryant SP, et al. N-terminal deletion in a desmosomal cadherin causes the autosomal dominant skin disease striate palmoplantar keratoderma. *Hum Mol Genet* 1999; 8(6): 971-6.
30. Armstrong DK, McKenna KE, Purkis PE, Green KJ, Eady RA, Leigh IM, et al. Haploinsufficiency of desmoplakin causes a striate subtype of palmoplantar keratoderma [published erratum appears in *Hum Mol Genet* 1999 May;8(5):943]. *Hum Mol Genet* 1999; 8(1): 143-8.

31. Fischer J, Bouadjar B, Heilig R, Fizames C, Prud'homme JF, Weissenbach J. Genetic linkage of Meleda disease to chromosome 8qter. *Eur J Hum Genet* 1998; 6(6): 542-7.
32. Vohwinkel KH. Keratoma hereditarium mutilans. *Arch. Derm. Syph.* 1929; 158: 354-364.
33. Bergman R, Bitterman-Deutsch O, Fartasch M, Gershoni-Baruch R, Friedman-Birnbaum R. Mal de Meleda keratoderma with pseudoainhum. *Br J Dermatol* 1993; 128(2): 207-12.
34. Sharma RC, Sharma AK, Sharma NL. Pseudo-ainhum in discoid lupus erythematosus [letter]. *J Dermatol* 1998; 25(4): 275-6.
35. Maestrini E, Korge BP, Ocana-Sierra J, Calzolari E, Cambiaghi S, Scudder PM, et al. A missense mutation in connexin26, D66H, causes mutilating keratoderma with sensorineural deafness (Vohwinkel's syndrome) in three unrelated families. *Hum Mol Genet* 1999; 8(7): 1237-43.
36. Kelsell DP, Wilgoss AL, Richard G, Stevens HP, Munro CS, Leigh IM. Connexin mutations associated with palmoplantar keratoderma and profound deafness in a single family. *European Journal of Human Genetics* 2000; 8(2).
37. Kelsell DP, Dunlop J, Stevens HP, Lench NJ, Liang JN, Parry G, et al. Connexin 26 mutations in hereditary non-syndromic sensorineural deafness [see comments]. *Nature* 1997; 387(6628): 80-3.
38. Xia JH, Liu CY, Tang BS, Pan Q, Huang L, Dai HP, et al. Mutations in the gene encoding gap junction protein beta-3 associated with autosomal dominant hearing impairment [see comments] [published erratum appears in *Nat Genet* 1999 Feb;21(2): 241]. *Nat Genet* 1998; 20(4): 370-3.
39. Maestrini E, Monaco AP, McGrath JA, Ishida-Yamamoto A, Camisa C, Hovnanian A, et al. A molecular defect in loricrin, the major component of the cornified cell envelope, underlies Vohwinkel's syndrome. *Nat Genet* 1996; 13(1): 70-7.
40. Takahashi H, Ishida-Yamamoto A, Kishi A, Ohara K, Iizuka H. Loricrin gene mutation in a Japanese patient of Vohwinkel's syndrome. *J Dermatol Sci* 1999; 19(1): 44-7.
41. Kibar Z, Der Kaloustian VM, Brais B, Hani V, Fraser FC, Rouleau GA. The gene responsible for Clouston hidrotic ectodermal dysplasia maps to the pericentromeric region of chromosome 13q. *Hum Mol Genet* 1996; 5(4): 543-7.
42. Protonotarios N, Tsatsopoulou A, Patsourakos P, Alexopoulos D, Gezerlis P, Simitsis S, et al. Cardiac abnormalities in familial palmoplantar keratosis. *Br Heart J* 1986; 56(4): 321-6.
43. Coonar AS, Protonotarios N, Tsatsopoulou A, Needham EW, Houlston RS, Cliff S, et al. Gene for arrhythmogenic right ventricular cardiomyopathy with diffuse nonepidermolytic palmoplantar keratoderma and woolly hair (Naxos disease) maps to 17q21. *Circulation* 1998; 97(20): 2049-58.

**A U T H O R S ' A D D R E S S E S** *Sarah J. Hatsell BSc, research scientist, Centre for Cutaneous Research, 2 Newark Street, Whitechapel, London E1 2AT, UK*  
*David P. Kelsell PhD, senior lecturer, same address*