

# The results of cataract surgery in patients with Marfan's syndrome with the new CTR

Rezultati kirurškega zdravljenja katarakte z novo obliko CTR pri bolnikih z Marfanovim sindromom

Boris Malyugin

Moscow, Russian Federation

## Korespondenca/ Correspondence:

Boris Malyugin, MD  
mail: boris.malyugin@gmail.com

## Ključne besede:

kapsularni tenzijski obroček, fakoemulzifikacija, subluksacija leče, Marfanov sindrom, oslabelost sprednje hialoidne membrane, šivanje beločnice

## Key words:

capsular tension ring, phacoemulsification, subluxated lens, Marfan's syndrome, zonular weakness, scleral suturing

## Citirajte kot/Cite as:

Zdrav Vestn 2012; 81: 1-61-66

Prispelo: 9. mar. 2012,  
Sprejeto: 3. maj 2012

## Abstract

Patients with profound zonular weakness and/or zonular dialysis require capsular tension rings to be sutured to the sclera in order to achieve capsular bag centration and long-term stabilization. We used the new, modified version of the capsular tension ring in 15 patients with Marfan's syndrome. In all cases favorable functional and anatomical results were achieved.

## Izvleček

Pri bolnikih s popolnim popuščanjem in/ali dializo sprednje hialoidne membrane je treba na beločnico prišiti kapsularni tenzijski obroček, da se doseže centriranje in dolgoročna stabilizacija kapsularne ovojnice. Novo, modificirano različico kapsularnega tenzijskega obročka smo uporabili pri 15 bolnikih z Marfanovim sindromom. V vseh primerih smo dosegli ugoden funkcionalni in anatomski rezultat.

## Introduction

The prerequisite of the modern cataract surgery is a healthy status of the lens zonular apparatus combined with adequate biomechanical properties of the capsular tissue. Patients with local and/or generalized zonular weakness present significant challenges for the surgeon. This is most often seen in cases of trauma, pseudoexfoliation syndrome, glaucoma, high myopia, hereditary systemic diseases (Marfan's syndrome, homocystinuria, Weill-Marchesani syndrome, etc.) and some others. One can expect in these patients an increased risk of capsular tears, vitreous prolapse and IOL instability.

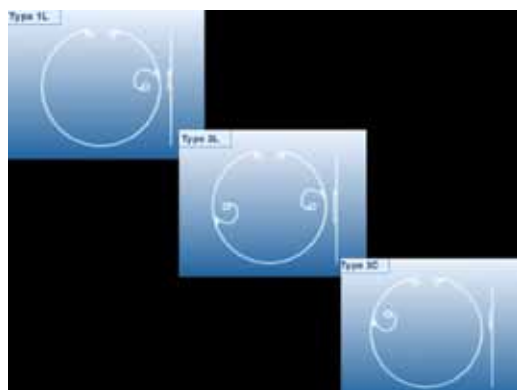
In many cases capsular tension rings (CTRs) are very useful in stabilizing crystalline lens during cataract surgery and reducing the likelihood of intraoperative complications.<sup>1,2</sup> These devices, which are used to maintain the circular contour of the capsular equator during surgery through stretching of the capsular bag, also prevent collapse and aspiration of the capsule, distribute forces equally over all zonules, and

prevent vitreous prolapse into the anterior chamber.

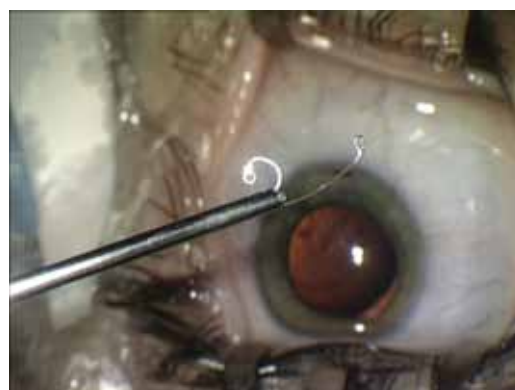
To address moderate and profound cases of zonular weakness, Dr. Cionni modified the standard CTR adding the fixation eyelet attached to the central portion of the ring.<sup>3</sup> This eyelet allows the ring to be sutured to the sclera and to provide intraoperative support during phacoemulsification. Cionni-modified CTR (Morcher GmbH, Germany) is a useful tool, which can be recommended for patients with zonular dialysis exceeding the area of 3 clock hours. However the segment of the ring attached to the fixation element does not allow the device to be fully retracted inside the injector tube (Fig. 2). Subsequently, most surgeons implant the device manually through the relatively large incision utilizing forceps.<sup>4</sup>

Malyugin CTR (Morcher GmbH, Germany) is a new endocapsular support device, developed to address the difficulties of microincisional cataract surgery in patients with large zonular dialysis or zonular weakness. It is designed to center the subluxated

**Figure 1 (left):** Different versions of the Cionni modified capsular tension ring.



**Figure 2 (right):** Retraction of the Cionni modified CTR into the injector is limited by the presence of the fixation element.



lens capsule by securing it to the scleral wall (Figure 4).

The basic idea of this device design consists of moving the fixation element to the very tip of the ring. This makes the device completely retractable into the injector tube, subsequently allowing it to be used through 2.2 mm incision. Also the curved portion of the CTR slides along the equator of the capsular bag during its injection. Thus the risk of perforating the capsular fornix with the tip of the CTR is eliminated.<sup>5</sup>

In this article we present our experience with the modified CTR in patients with severe lens subluxations of the hereditary origin.

## Materials and Methods

Modified CTR was used in 15 patients (15 eyes) with Marfan's syndrome. Mean age of the patients was  $21.5 \pm 11.3$  years. There were 9 females and 6 males.

Preoperatively, BCVA varied from 0.3 to counting fingers, with IOP within normal limits. The extent of the zonular defect assessed by ultrasonic biomicroscopy (UBM)

varied between 60 and 210 degrees (mean 97 degrees).

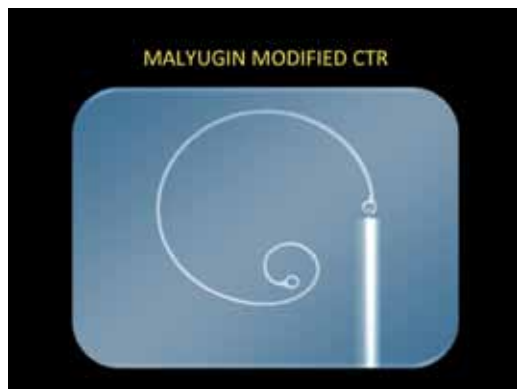## Surgical technique

After creating clear corneal incision, capsulotomy is initiated with the sharp bent needle. Microcapsulorhexis forceps are used to grasp the flap and to tear the capsule in the circular manner. In many cases capsular folds and lens instability during the capsulorhexis can be observed, which presents an additional evidence of significant zonular pathology.

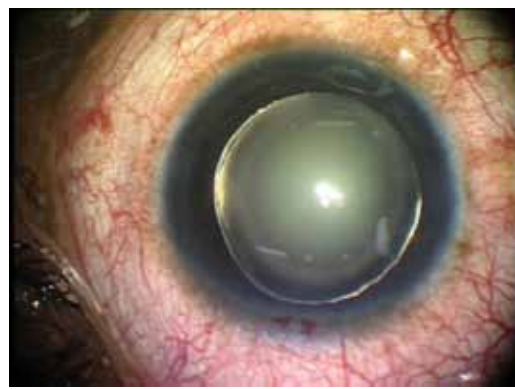The Malyugin CTR is retracted into the injector cartridge. The needle is passed through the eyelet in order to fixate it with 9/0 polypropylene suture.

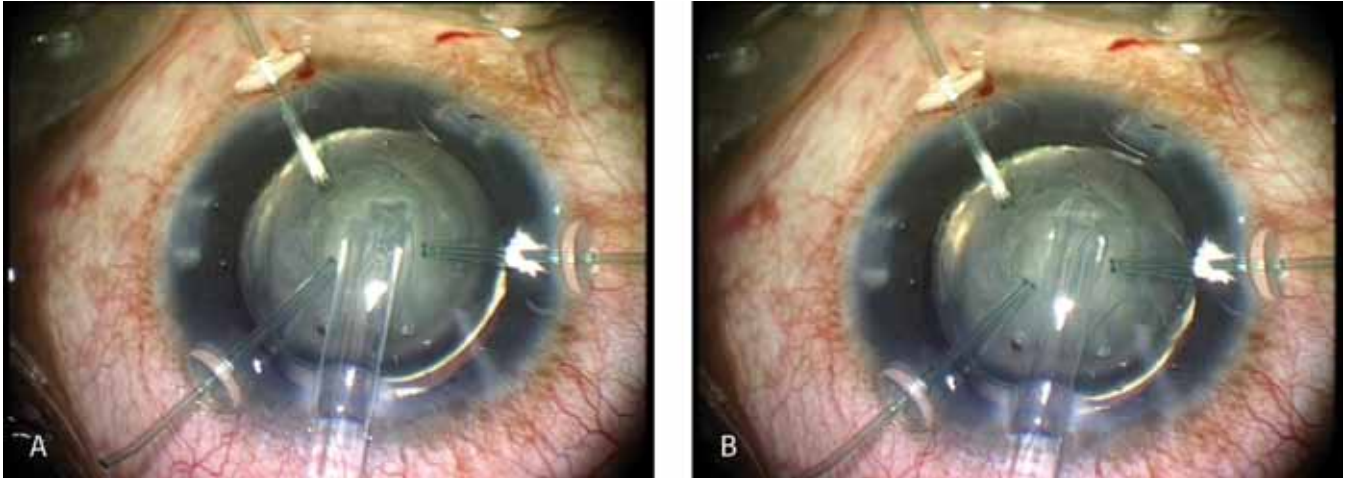
During the implantation, injector is positioned in the center of the anterior chamber. By pushing the plunger, the surgeon slowly inserts the ring right under the anterior capsule into the capsular bag (Figure 5). The ring is injected in the direction of the zonular defect in order to prevent damaging of the residual zonules. Curved fixation element safely slides along the equator of the capsular bag without any risk of damaging

**Figure 3 (left):** Malyugin modified capsular tension ring (CTR).



**Figure 4 (right):** Eye of a patient with Marfan's syndrome at the beginning of the surgery.





**Figure 5 a,b:** Malyugin CTR (Mocrcher GmbH) is injected into the capsular bag. Injector plunger hook holding the Malyugin CTR eyelet can be visualized through the transparent plastic injector tube.

it (Fig. 6). Trailing end of the device is guided under the fixation element and released from the injector plunger (Figure 7). Using the Sinsky hook, CTR is rotated in order to position the fixation element right in the center of the zonular defect.

Conjunctival flap is created with scissors followed by gentle cautery of the episcleral vessels. The needle is passed through the ciliary sulcus with an ab interno approach. Fixation element is guided out of the bag through the capsulorhexis opening with the help of reversed Sinsky hook and positioned on the anterior surface of the sclera.

After needle externalization, it is then fixated to the superficial scleral layers in the zig-zag fashion with 4–5 bites, followed by tying the double knot.

Multiple-quadrant hydrodissection is performed carefully. It is followed by phacoemulsification with the Stellaris system (Bausch & Lomb) utilizing the quick-chop technique of nucleus disassembly. Ultrasound is linear with the dual linear footpedal control that helps to stabilize the anterior

chamber and to increase the safety margin of the whole procedure (Figure 9).

After the last fragment of nucleus is removed, cortical material is aspirated from the capsular bag with bimanual irrigation-aspiration system (Figure 10). Foldable acrylic IOL is injected into the capsular bag (Figure 11). Leading haptic element goes directly into the bag, while the trailing haptics is, in most cases inserted bimanually by gently holding the capsulorhexis edge with microhook and using the second instrument to advance the haptic inside the bag.

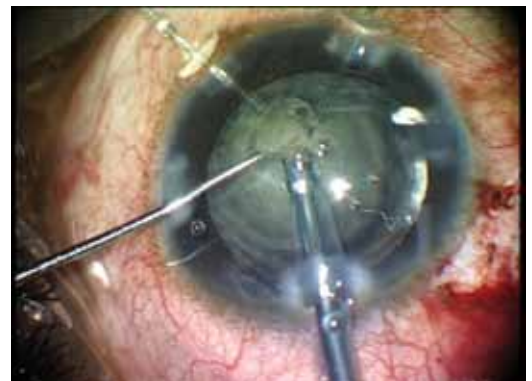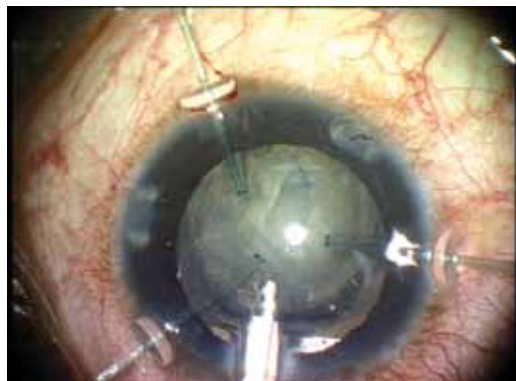Conjunctiva is closed with two or three 8/0 vicryl interrupted sutures placed in the limbal area. At the end of the case stable position of the capsular bag and IOL is achieved.

## Results

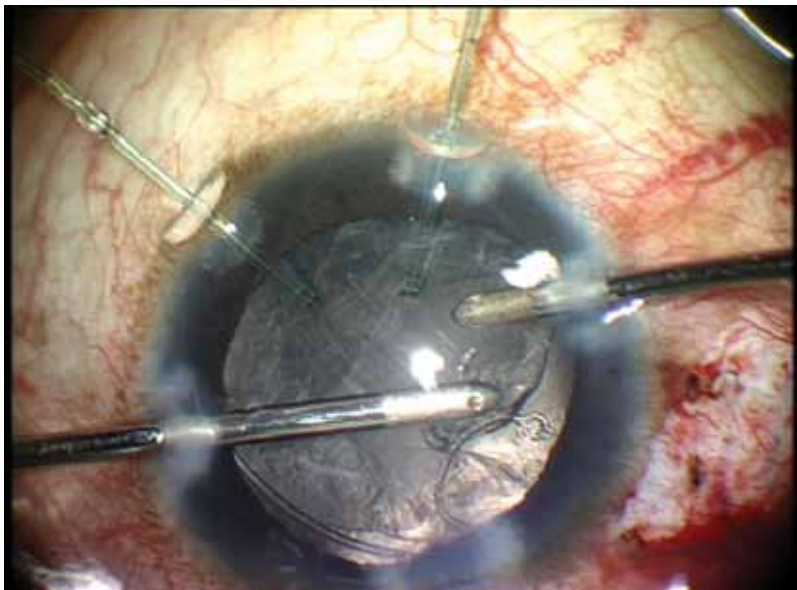
Mean follow-up duration was  $22.5 \pm 4.7$  months. BCVA improved to the mean 0.7 after surgery. No major complications were observed during surgery. PCO was the most

**Figure 6 (left):** The eyelet of the ring is released from the injector hook (facing down) at the final steps of ring implantation.

**Figure 7 (right):** After suturing the CTR to the sclera, phacoemulsification is being performed.







**Figure 8:** Irrigation-aspiration of the cortical material with the bimanual I/A handpieces (Duet system, MST).

frequent finding in the postoperative period and occurred in 9 eyes, 5 of which required YAG capsulotomy.

Capsular bag and IOL position were verified by ultrasonic biomicroscopy (Figure 11). In all patients they were positioned centrally, mean shift in the direction of the traction suture was  $0.36 \pm 0.29$  mm, and the lense tilt  $5.2 \pm 3.1$  degrees. IOP was within normal range.

## Discussion

Currently, we are at the time point when cataract surgery has progressed significantly, however, zonular compromise still presents a very significant challenge and raises the risk of intra- and postoperative complications, including IOL long-term stability.

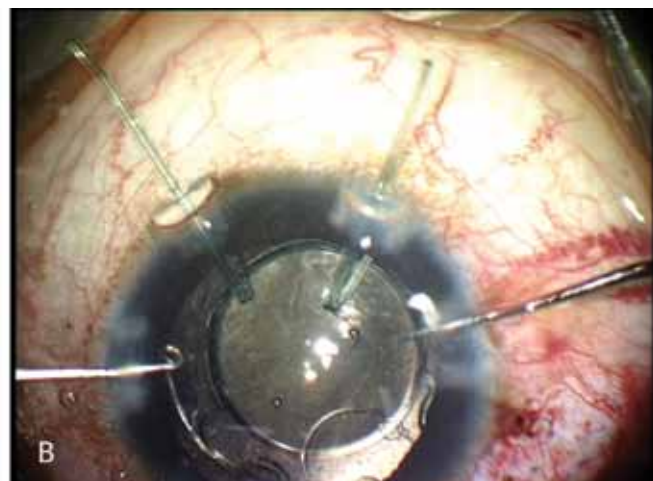
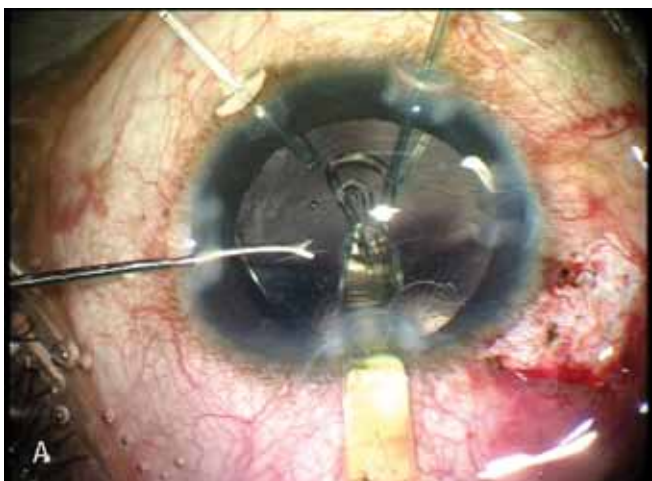
There are several types of devices designed to facilitate cataract surgery in patients with zonular dialysis. For instance, flexible iris retractors can be used to support the capsular bag in the presence of extremely loose zonules.<sup>6</sup> However, because of their short and flexible hooked ends, iris retractors tend to slip off and in some cases tear the anterior capsulorhexis.

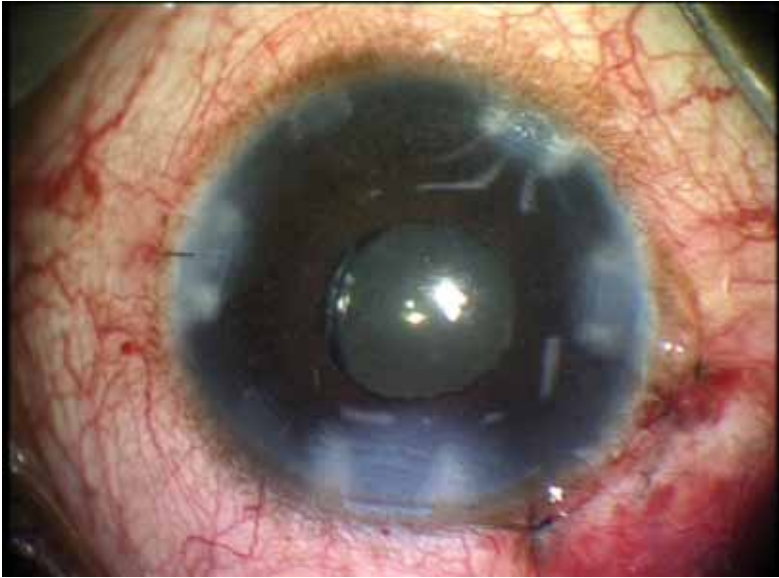
Specially designed capsule retractors made of titanium or plastic, including the capsule support system (Duckworth and Kent Ltd., UK), MST capsule retractors (MicroSurgical Technology Inc., USA) have hooked ends, which are elongated enough to support the peripheral capsular fornix and do not damage the capsulorhexis. These devices function like temporary artificial zonules fixating the whole capsular bag to the limbal area.

Capsular tension segments (Ike Ahmed, 2001), Assia Anchor (Ehud Assia, 2005), suture with a T-shaped end (R. Yamaguchi 2008) (Figure 3) both have the advantage of minimizing surgical trauma and providing the permanent zonular replacement not only during surgery but also in the long term after it.<sup>7</sup> The main disadvantage of the above-mentioned devices is that they can provide only focal support of the capsular bag and do not totally restore its equator shape. That is why in many cases their combination with a conventional or modified CTR is mandatory.

Conventional and modified CTRs provide numerous benefits to surgeons managing challenging cataracts with weakened zonu-

**Figure 9 a,b:** Hydrophilic acrylic yellow tinted IOL Micro AY (Physiol SA) is being injected into the capsular bag (a). IOL haptics is then positioned in place with the help of 2 instruments introduced through the paracentheses (b).





**Figure 10:** The eye of a patient at the final steps of the surgery.

les. The ongoing development of endocapsular devices allows for removal of cataract in complicated cases with weak or absent zonules as well as providing fixation of the capsular bag to the sclera.

One of the benefits of a CTR in postoperative period is that it counters progressive contractile centripetal forces and resists capsulorhexis shrinkage as the capsular bag contracts. This is a very likely scenario in pseudoexfoliation syndrome in which

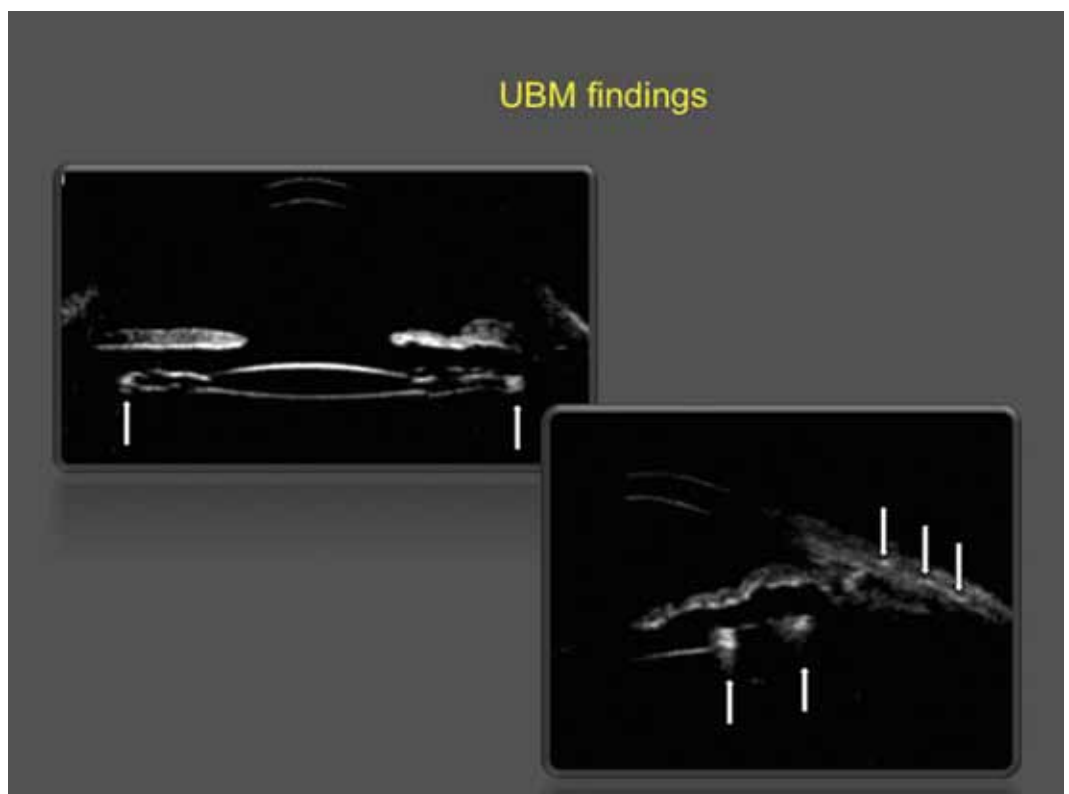
the entire capsular bag dislocates years following the initial surgery.<sup>8,9</sup> The downside of CTR is technical complication of irrigation-aspiration phase of the surgery because of the trapping of the cortical material at the equator of the capsular bag, which makes aspiration process more challenging. This can be overcome by using the bi-manual I/A systems and stripping the cortex in the tangential direction.

## Conclusions

The Malyugin modified CTR is a novel capsular expansion device designed to be injected through a microincision and to center the subluxated capsule by securing it to the scleral wall. The modified CTR allows the loose eccentric capsules to be recentered and secured achieving safe endocapsular implantation and long-term stability of the capsular bag.

Based on the results of this study, we came to the conclusion that a combination of the Malyugin CTR scleral suturing and clear corneal phacoemulsification provided favorable functional and anatomical results.

**Figure 11:** Ultrasonic biomicroscopy in the postoperative period. IOL is positioned centrally. CTR (white arrows) can be visualized in the equatorial zone of the capsular bag (left picture). Intrasceral sutures are seen as a three white dots in the cross-sectional UBM view (pointed by white arrows).



## References

1. Hara T, Hara T, Yamada Y. "Equator ring" for maintenance of the completely circular contour of the capsular bag equator after cataract removal. *Ophthalmic Surg.* 1991; 22: 358–359.
2. Cionni R, Osher R. Endocapsular ring approach to the subluxed cataractous lens. *J Cataract Refract Surg.* Vol. 21, May 1995; P. 245–249.
3. Cionni R, Osher R. Management of profound zonular dialysis or weakness with a new endocapsular ring designed for scleral fixation. *J Cataract Refract Surg.* Vol. 24, October 1998; P. 1299–1306.
4. Moreno-Montanes J, Sainz C, Maldonado MJ. Intraoperative and postoperative complications of Cionni endocapsular ring implantation. *J Cataract Refract Surg* 2003; 29: 492–497.
5. Malyugin B, Golovin A. Long-Term Results of Cataract Surgery in Patients With Traumatic Zonular Dialysis and Mydriasis. Paper presented at: ASCRS/ASOA Symposium on Cataract, IOL, and Refractive Surgery; March-April, 2011; San Diego, California.
6. Merriam JC, Zheng L. Iris hooks for phacoemulsification of the subluxated lens. *J Cataract Refract Surg.* 1997; 23: 1295–1297.
7. Ahmed I, Kranemann C, Crandall A. Capsular hemi-ring: next step in effective management of profound zonular dialysis. Paper presented at: ASCRS/ASOA Symposium on Cataract, IOL, and Refractive Surgery; April 12–13, 2003; San Francisco, California.
8. Jahan FS, Mamalis N, Crandall AS. Spontaneous late dislocation of intraocular lens within the capsular bag in pseudoexfoliation patients. *Ophthalmology.* 2001; 108: 1727–1731.
9. Chang DF. Prevention of bag-fixated IOL dislocation in pseudoexfoliation (letter). *Ophthalmology.* 2002; 109:5–6.